Two Strip technique for Stabilization of the common AV valve with single ventricle palliation

Prof Mark Danton MD FRCS

Consultant Cardiac Surgeon

Scottish Paediatric and Adult Congenital Cardiac Services

Royal Hospital for Children | Golden Jubilee National Hospital, Glasgow

Professor Paediatric Cardiac Surgery, Cardiovascular & Metabolic Health, University of Glasgow

University of Glasgow

Scottish Paediatric Cardiac Services

Outline

- Common atrioventricular function in single ventricle palliation
- Technique of repair in standard/balanced AVSD
- A case of left atrial isomerism
- 2-strip technique of valve construction with cAVSD in SVP
- Discussion on alternative techniques, theoretical benefits of 2-strip technique and 2-ventricle considerations

Common atrio-ventricular valve

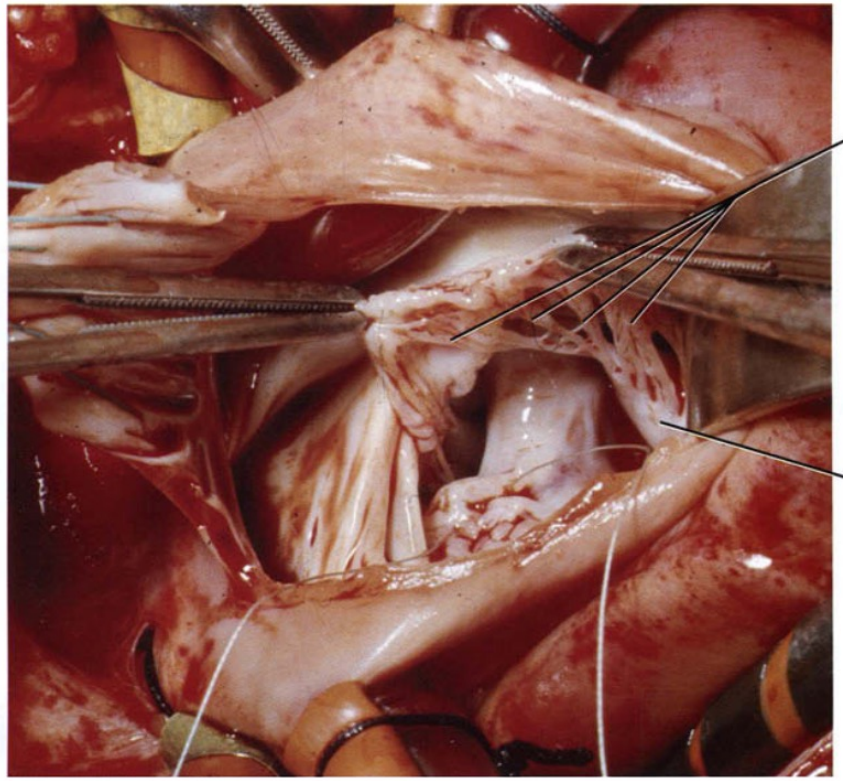

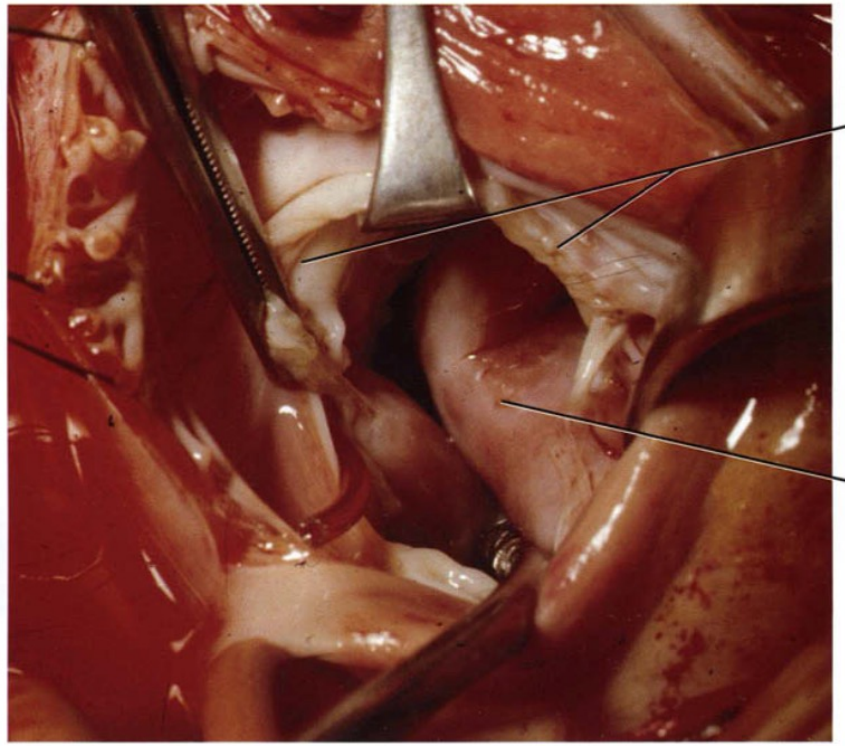

Commencement of Septation

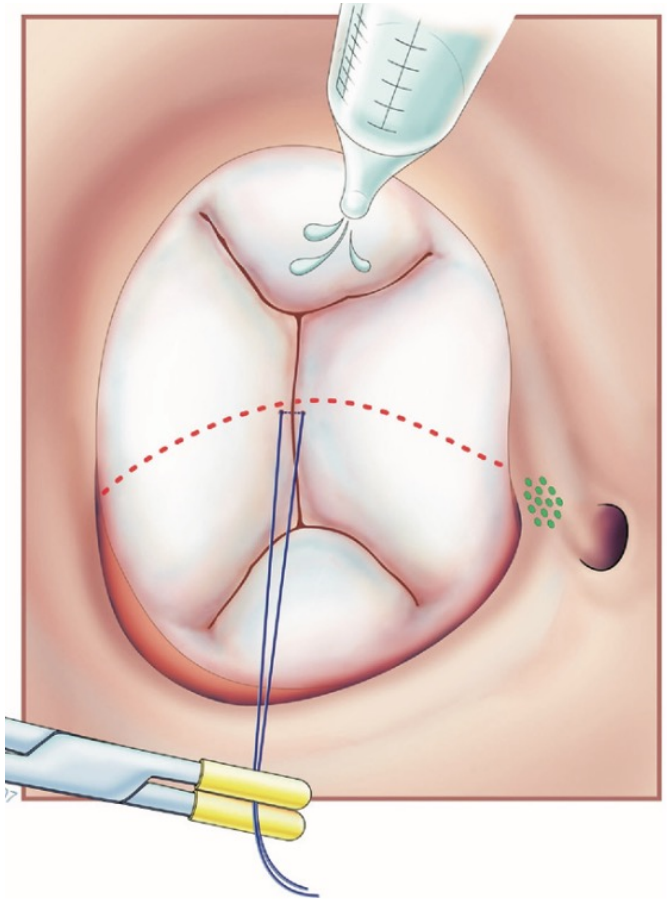

Defining line of septation on Bridging leaflets

- A critical part of the procedure
  - Mid-point of superior bridging leaflet
  - Chordal attachments balanced either side of the septal crest
  - Corresponding point on the inferior bridging leaflet identified in ‘end-diastole’
  - Marking suture to ensure and maintain alignment

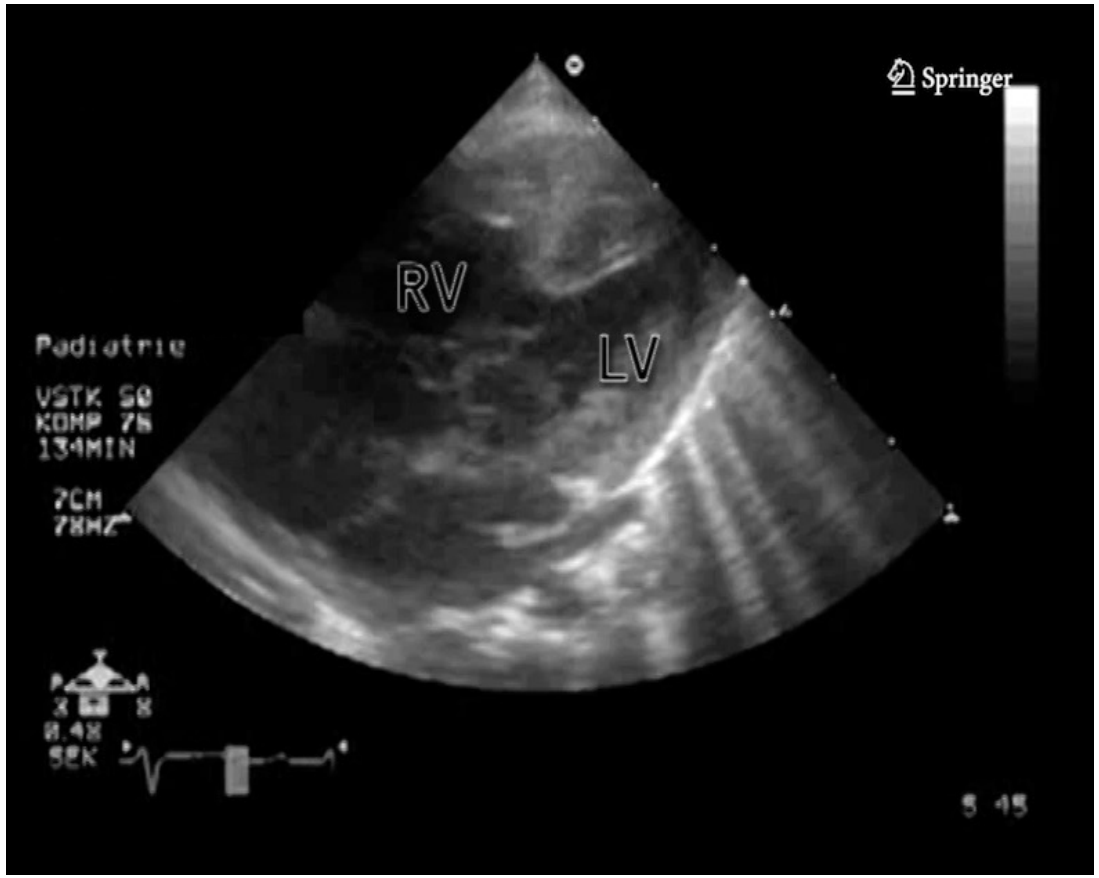

Video images courtesy V. Hraska

VSD closure

- Fixed autologous pericardium
  - Flexible to place under leaflets and weave within sub-valve apparatus without distortion
  - No degeneration
- Crescentic shape
  - Width = transverse annulus in mid diastole
  - Height = crest to annular plane +2-4mm
- Implant with interrupted plegeted sutures
  - Identify annulus – septal junction
  - Position within chords, respecting left-right orientation
- Check valve function

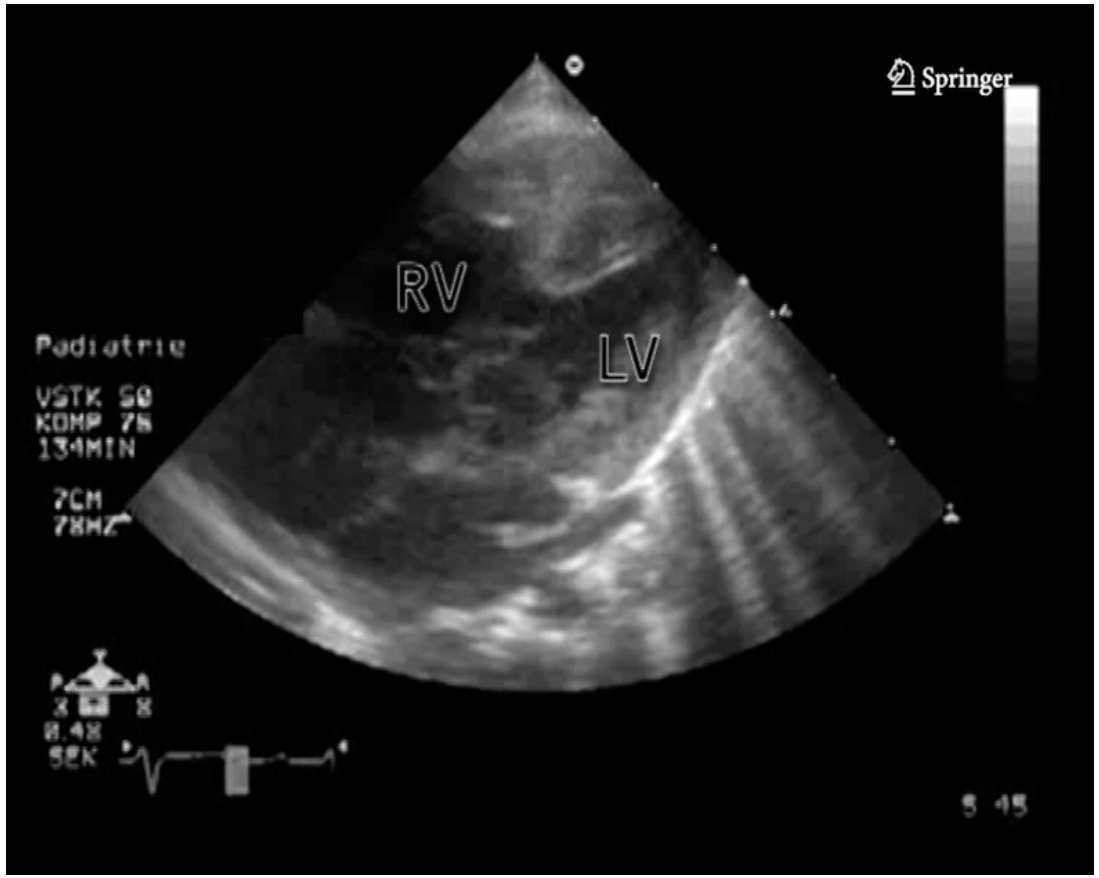

VSD closure

- Fixed autologous pericardium
  - Flexible to place under leaflets and weave within sub-valve apparatus without distortion
  - No degeneration
- Crescentic shape
  - Width = transverse annulus in mid diastole
  - Height = crest to annular plane +2-4mm
- Implant with interrupted plegeted sutures
  - Identify annulus – septal junction
  - Position within chords, respecting left-right orientation
- Check valve function

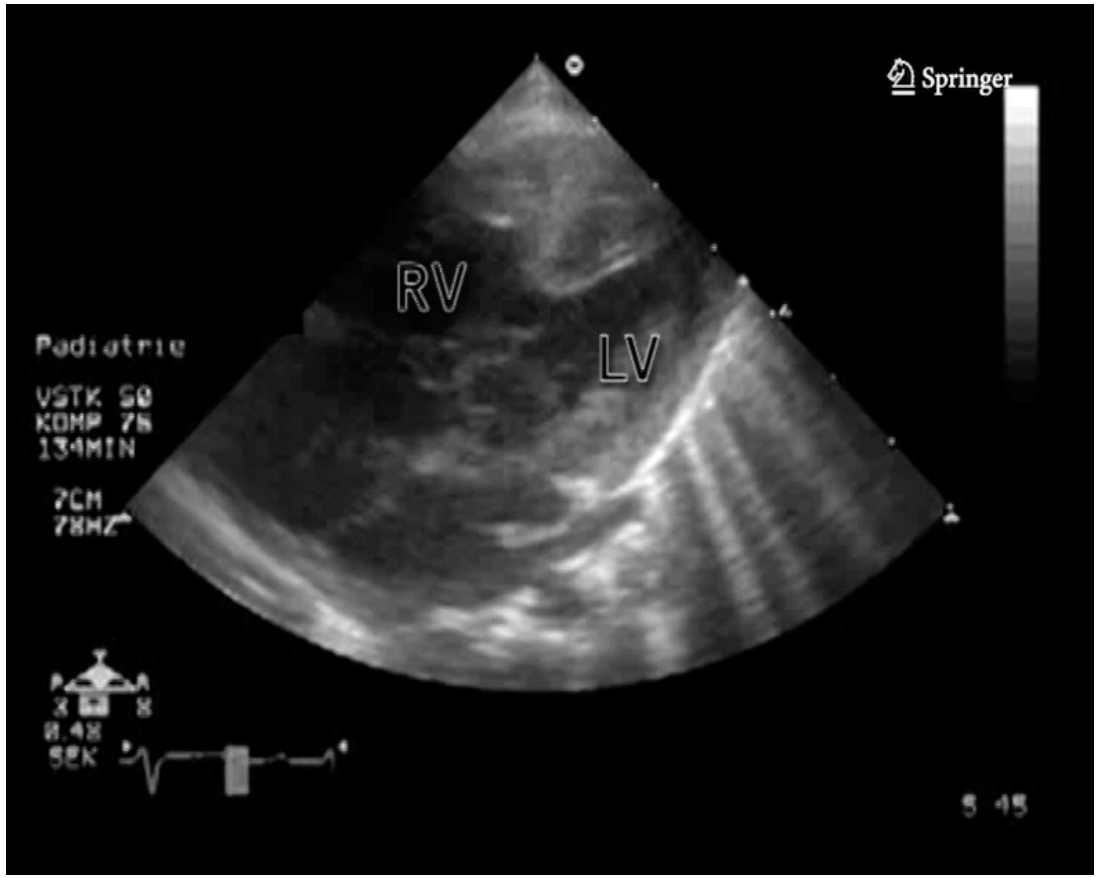

ASD patch

- Fresh autologous pericardium
  - Generous size, trim later
- Septation of bridging leaflets
  - U sutures: VSD patch attached to leaflets then into ASD patch
  - Follow line of septation incorporating original marking suture
  - Lower into place and tie out
- Check valve function

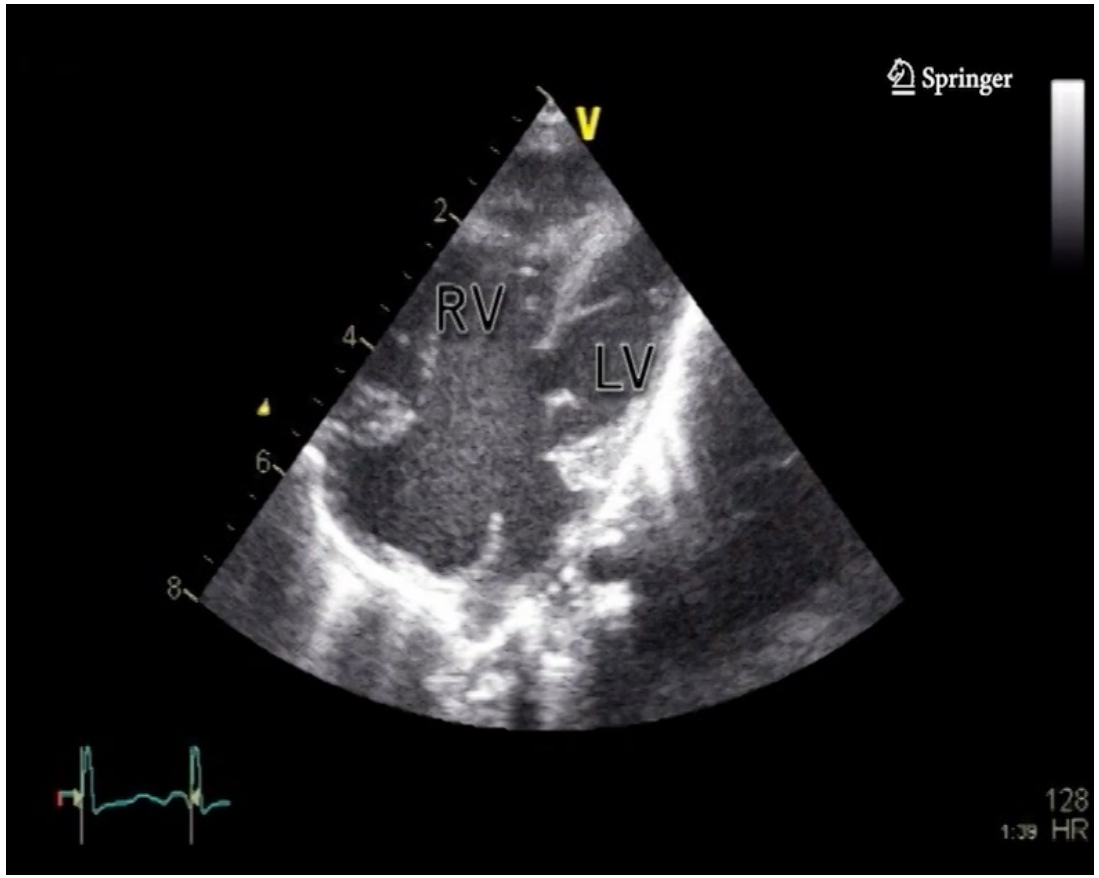

ASD patch

- Fresh autologous pericardium
  - Generous size, trim later
- Septation of bridging leaflets
  - U sutures: VSD patch attached to leaflets then into ASD patch
  - Follow line of septation incorporating original marking suture
  - Lower into place and tie out
- Check valve function

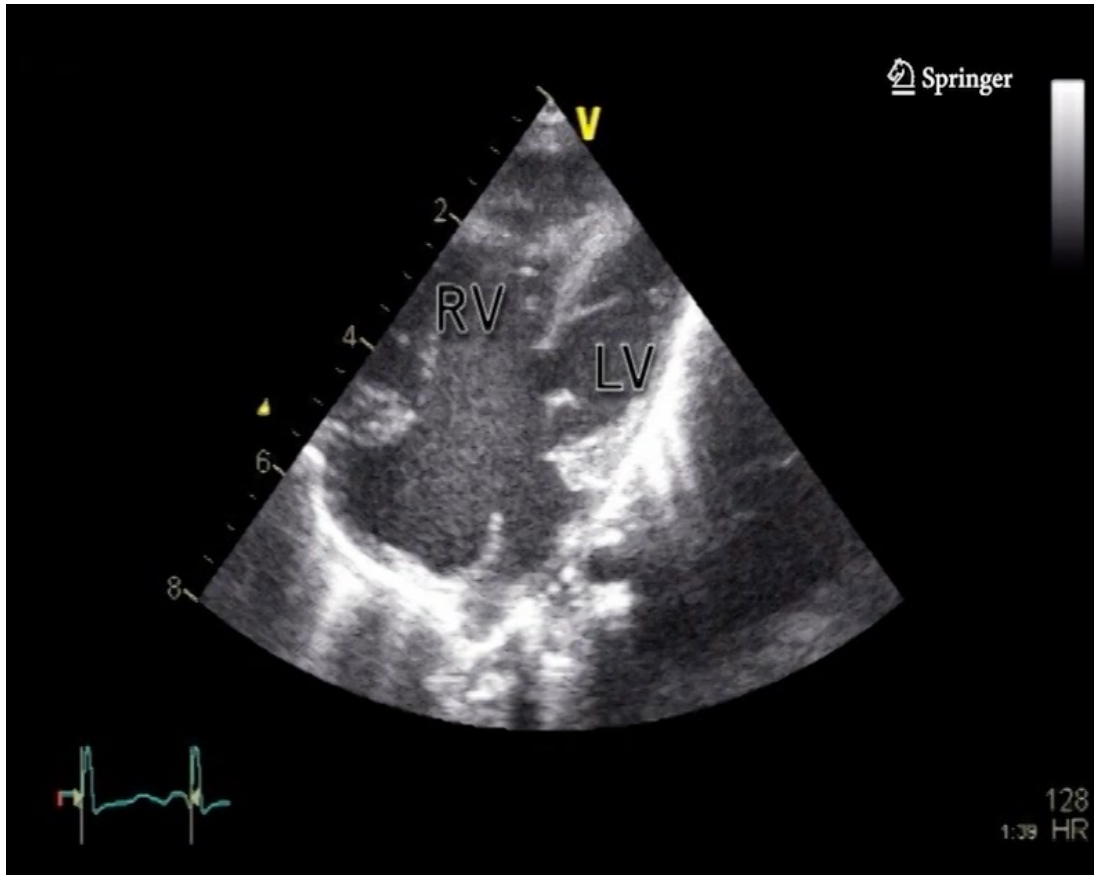

Left AV construction

- Assess leaflet geometry and function
  - Should be competent
- Define cleft
- Zone of apposition closure
  - Interrupted single or mattress
  - Non-plegleted
- Repeated testing of valve function

*No commissural plication required

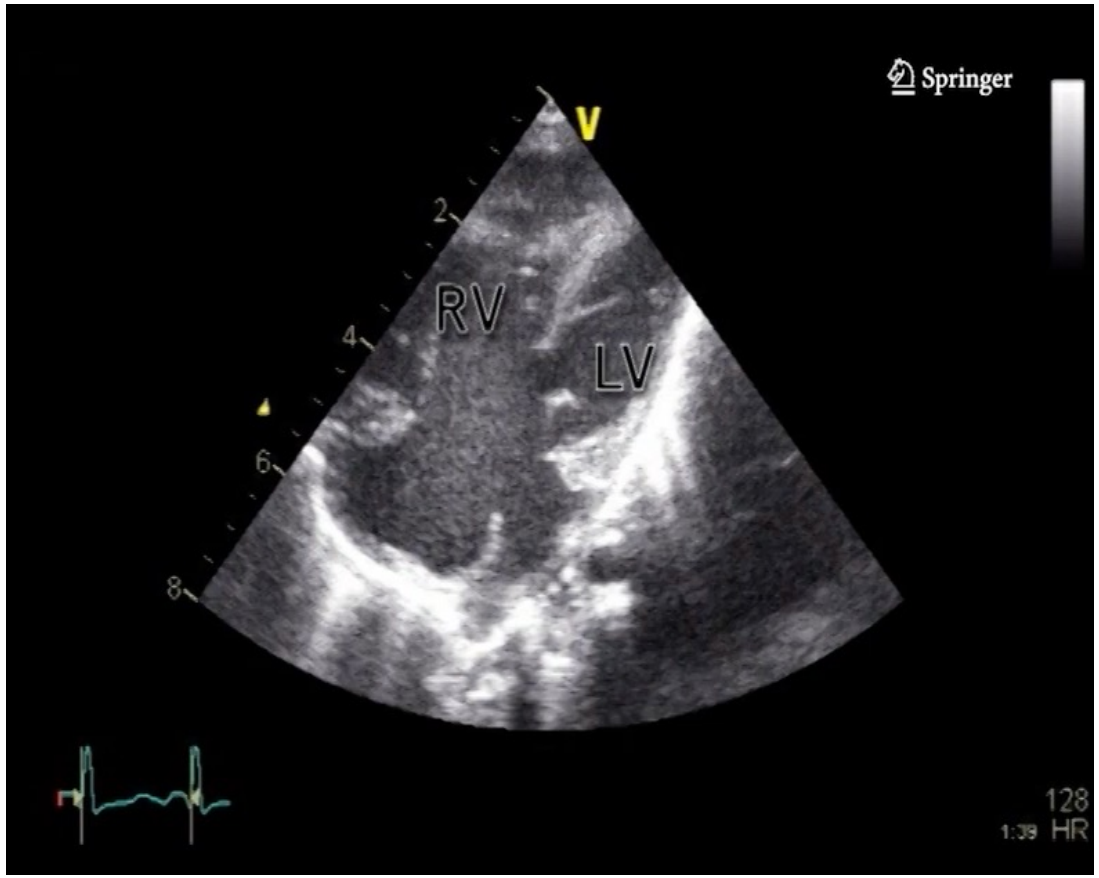

ASD closure

- Avoiding conduction tissue injury
  - Inferior suture line along left AV valve annulus
  - Large ‘bites’ on patch; light delicate on atrium
- Coronary sinus drains to right atrium

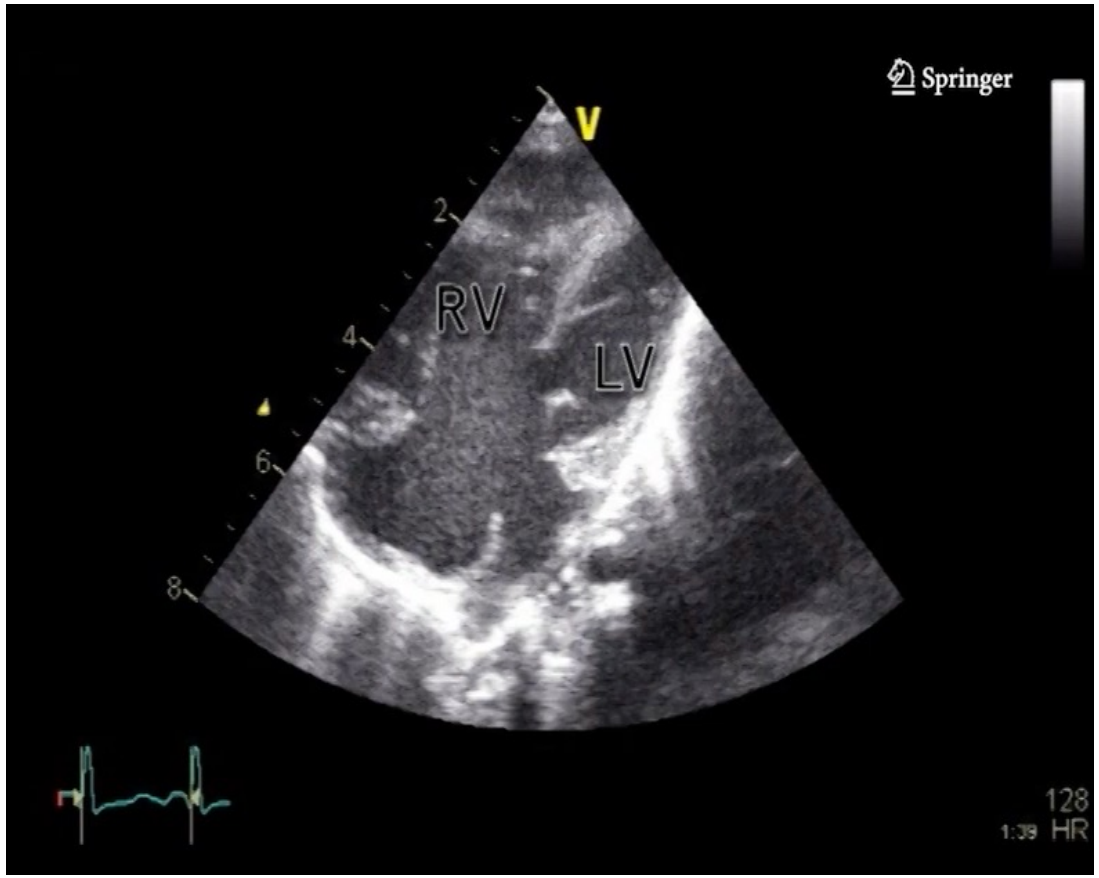

Right AV valve construction

- Assess right AV valve leaflets and function
  - Cleft
  - Leaflet tissue 360^0
- Closure of zone of apposition

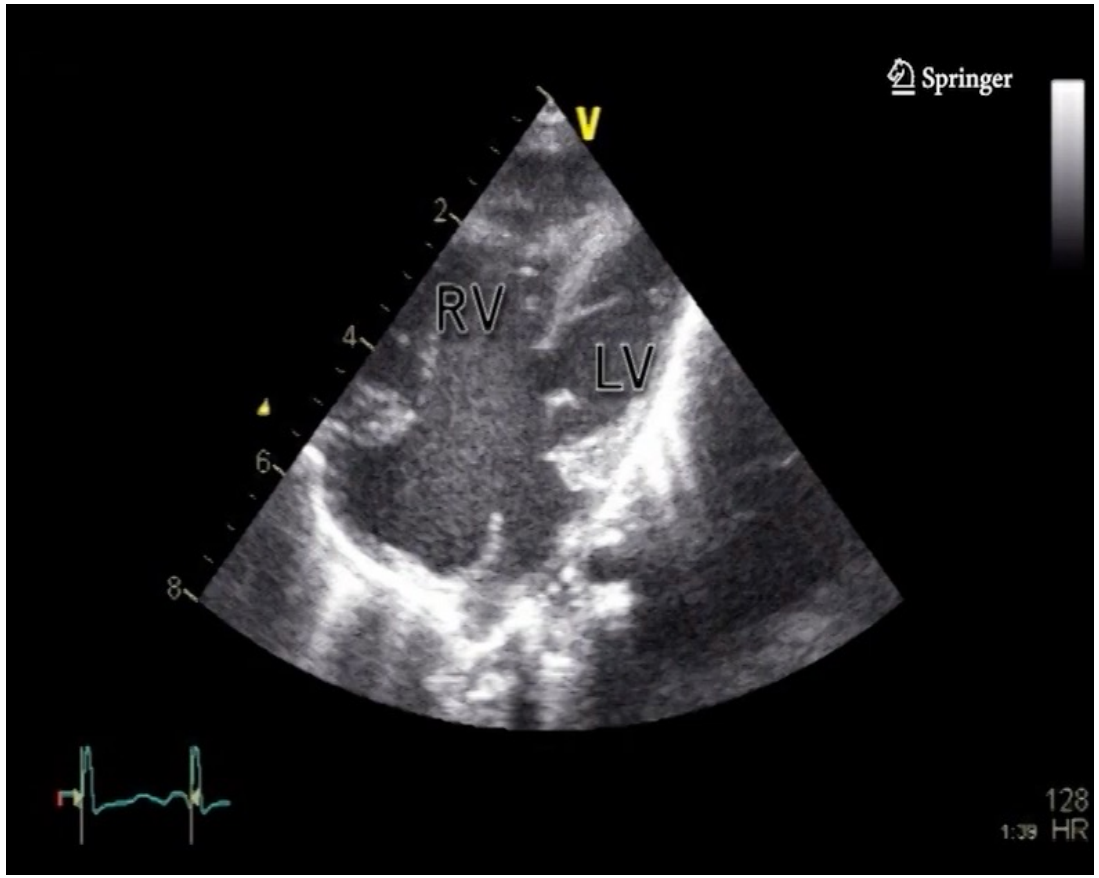

* Particularly important with TOF/AVSD & single ventricle palliation where right valve component is under systemic pressure

Case Presentation

- Male infant: 12th March, 2013
- Emergency C/S at 39 weeks gestation for fetal distress
- 2.6kg
- Normal genotype
- Stabilizes with resting SpO_2 ~ 83%

Morphology

- Left atrial isomerism
  - Bilateral Superior Vena Cava (dominant left)
  - Interrupted IVC with Hemi-azygous (and Azygous) continuation
  - Common atrium
  - Unobstructed Pulmonary venous drainage to common atrium left and right of midline

- Dominant RV with small/borderline LV
- Common AV valve, Large inlet VSD
- Double outlet RV with Aorta remote from VSD

Common Atrium, bilateral pulmonary veins

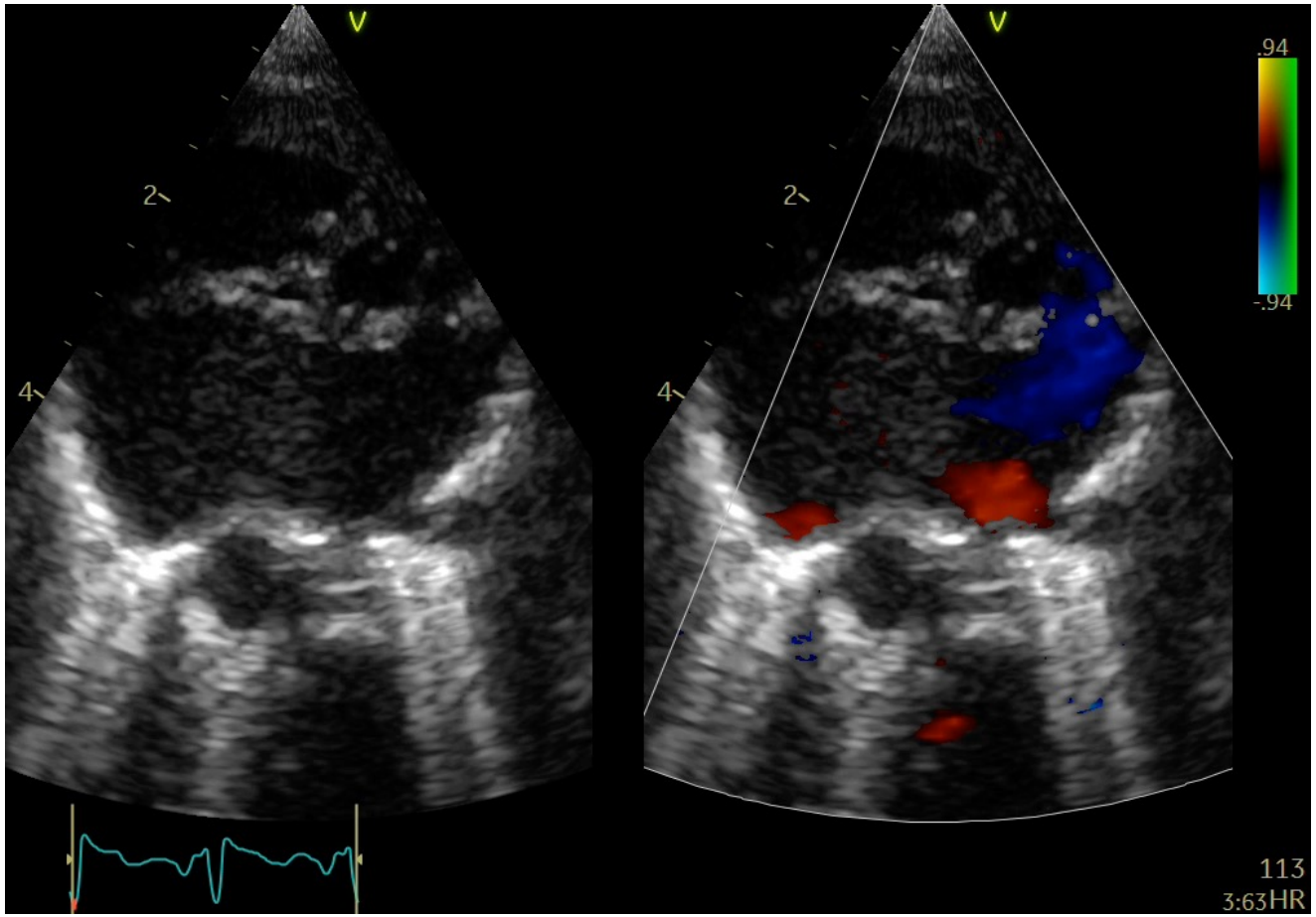

DORV: Remote Aortic valve

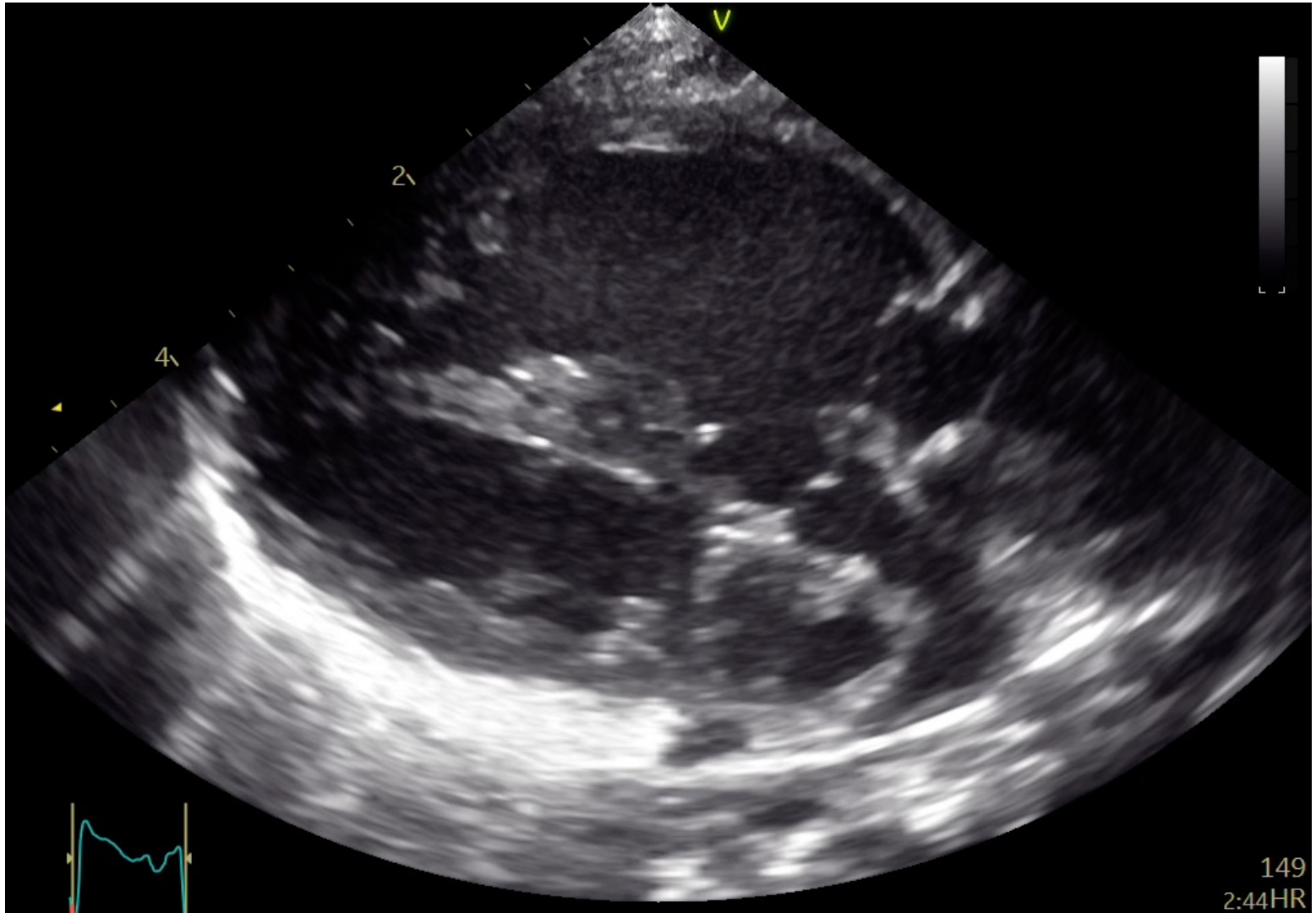

Common Atrio-ventricular valve

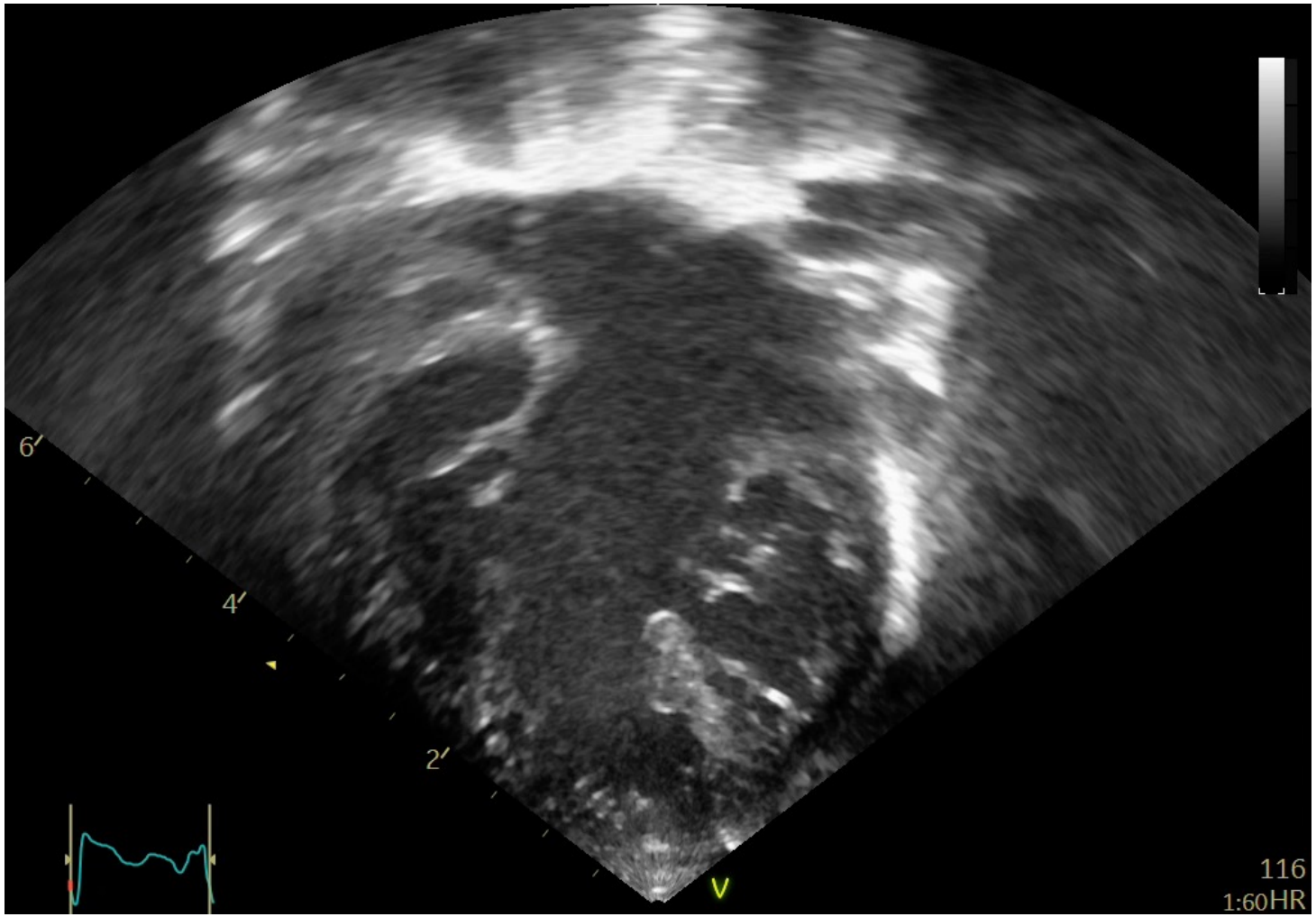

AV valve: Severe regurgitation

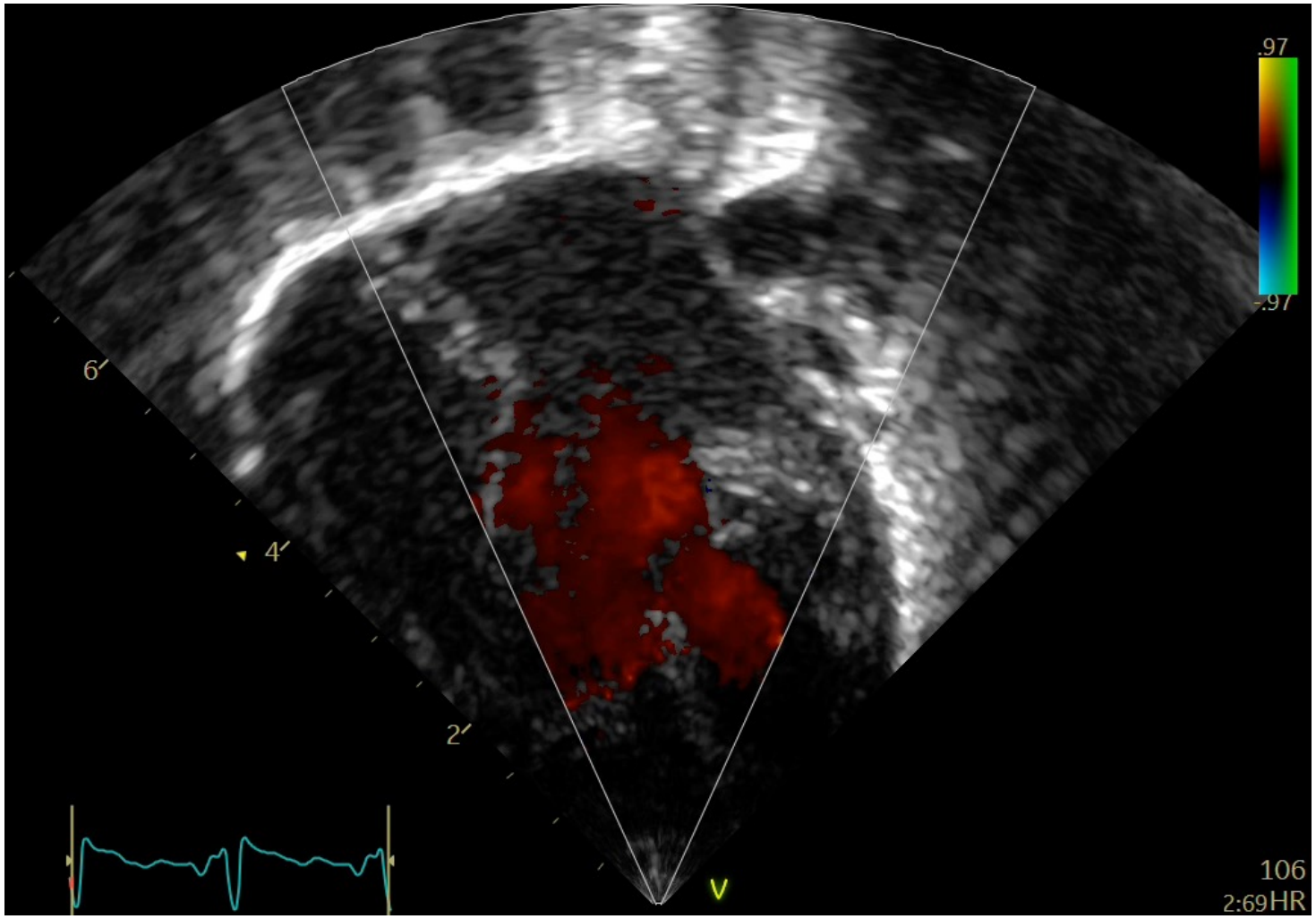

Inflow preferred to Right Ventricle

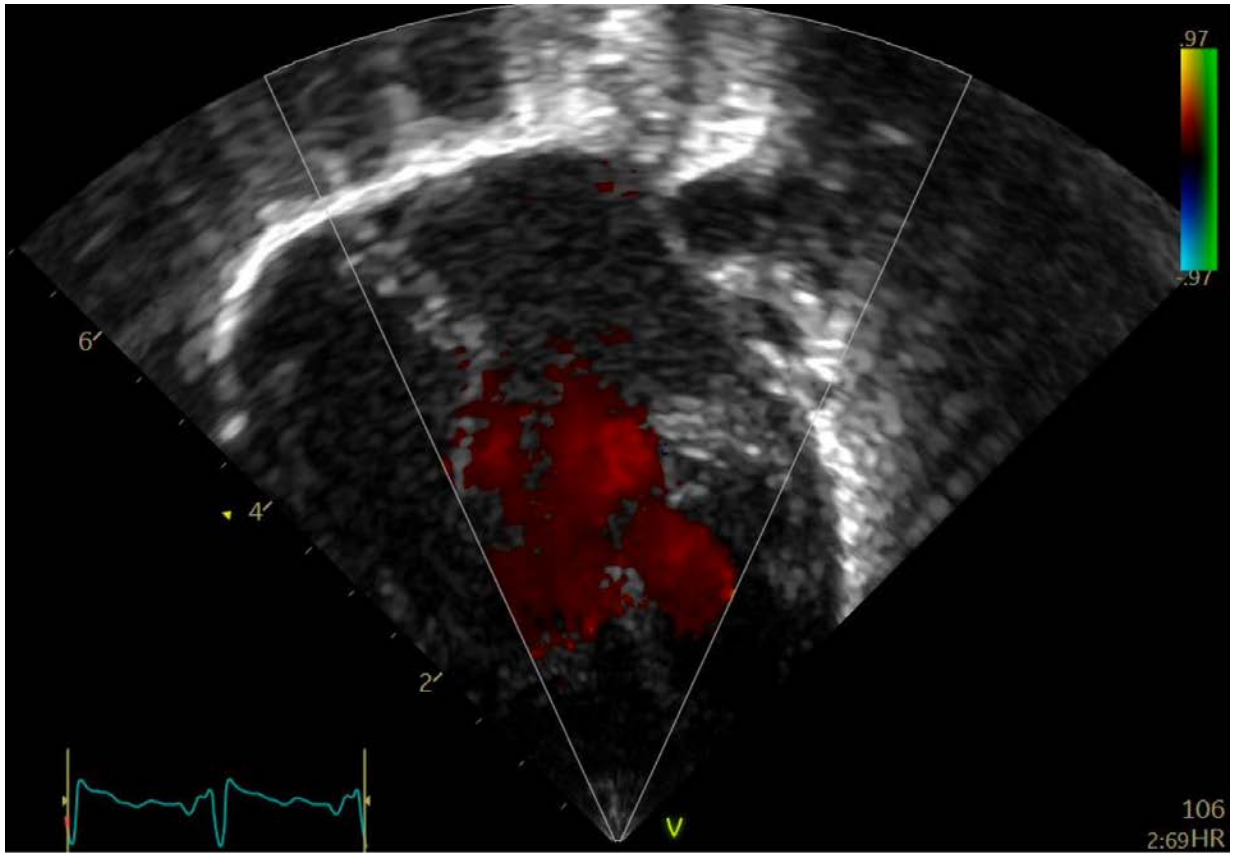

Inflow preferred to Right Ventricle

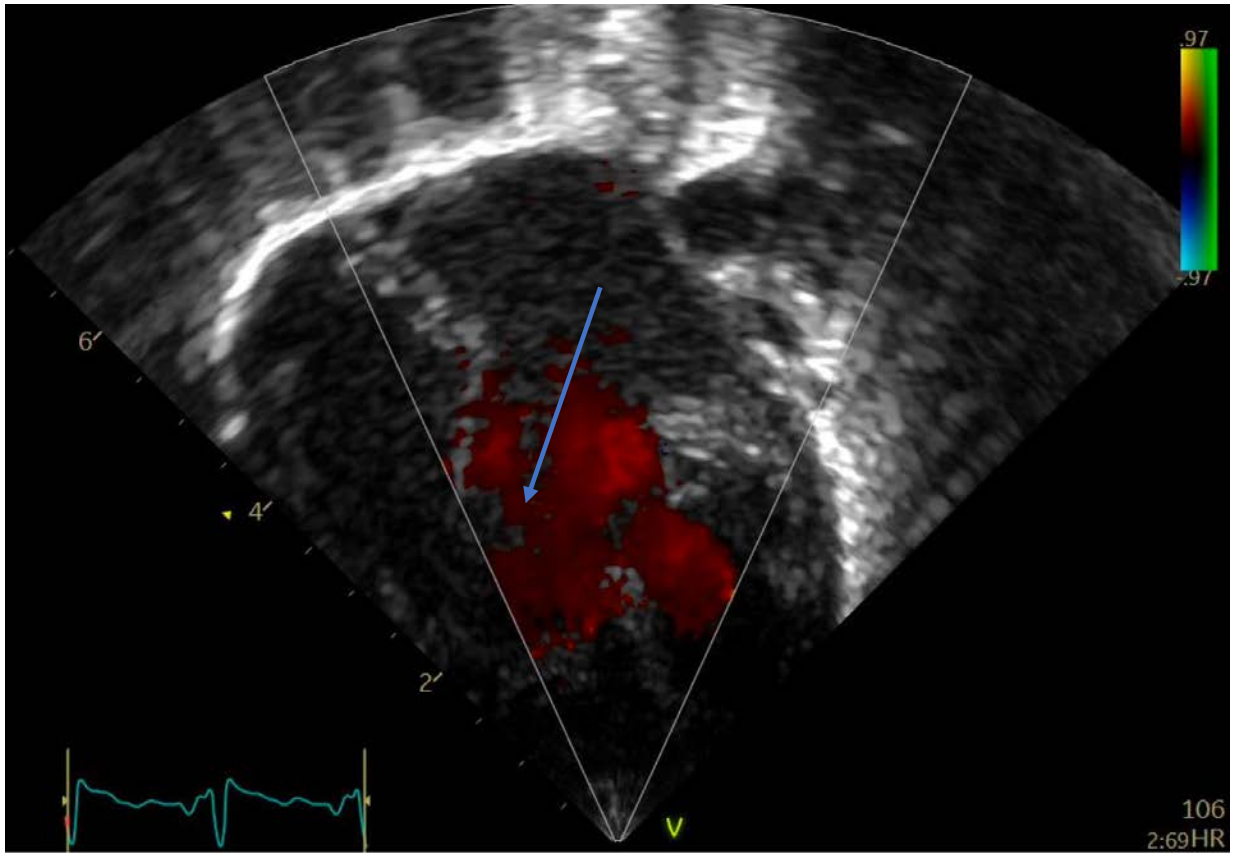

Pulmonary valve obstruction: Dysplastic 2 to 4.5m/sec

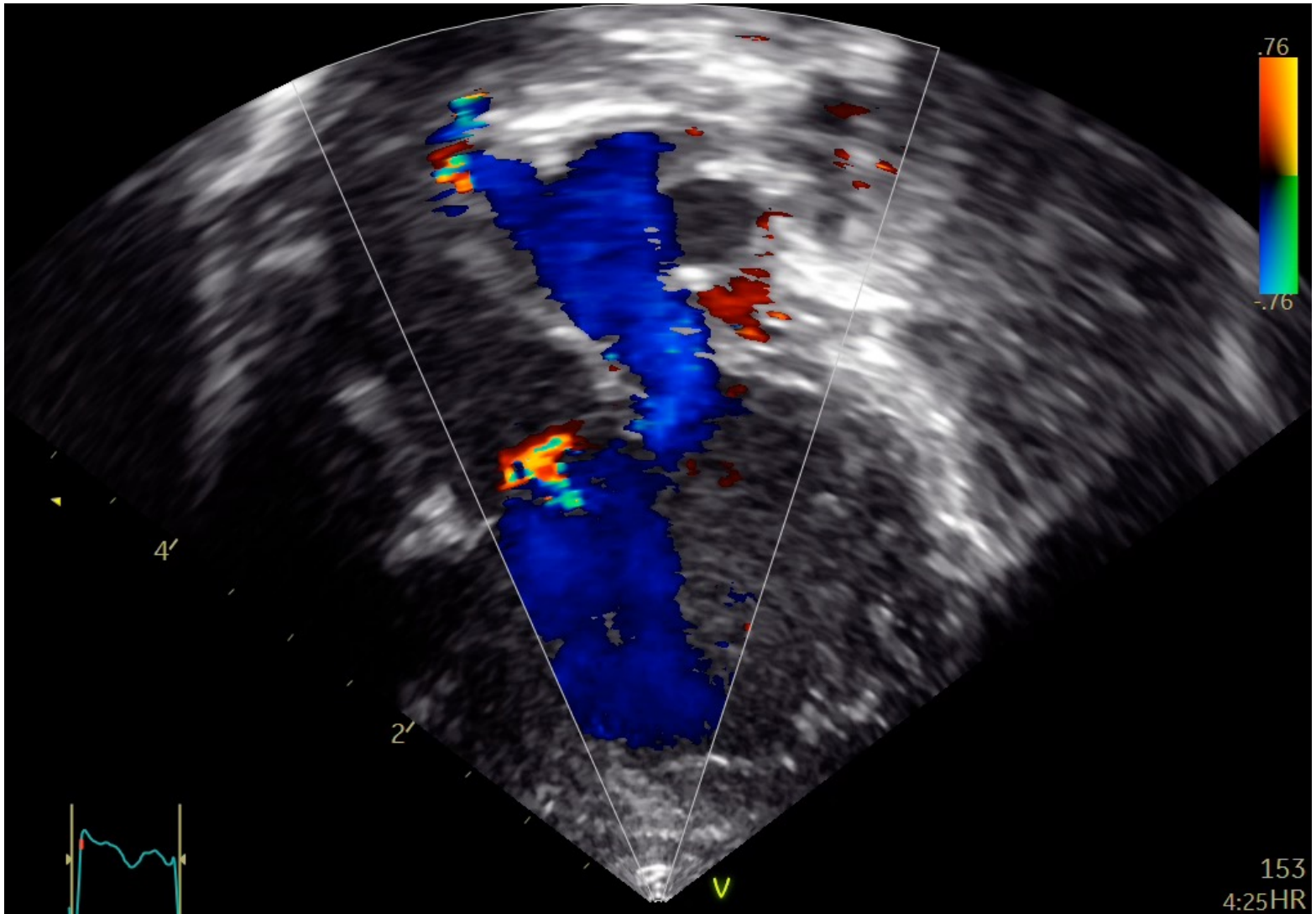

Initial Management

- Heart Failure treatment
- Surgical Options
  - Biventricular repair : LV borderline, Complex atrial and ventricular septation (Aorta remote from VSD)
  - Single ventricle palliation - Kawashima: Common AV valve function
  - Transplant
  - No surgery
- Discussion with Parents
  - Prognosis guarded
  - Hospice referral

Further Rx

- Ladds procedure for malrotation + gastrostomy
- Increase in pulmonary valve gradient to 4.7m/sec
- Control of heart failure
- Decrease in AV regurgitation
- Weight gain

Cardiac Catheter

- 7th July, 2014:
- Age 16 months, 8.15 kg
- Foreshortened LV apex
- Pressures
  - Common atrium = 5mmHg
  - LPA = 16mmHg RPA = 12mmHg
  - Mild narrowing at ductal inset
- Pulmonary Valve Gradient =30mmHg
- Suitable for Single ventricle Palliation

Two-Strip Technique to Repair Common Atrioventricular Valve Regurgitation in Single-Ventricle Palliation

Kasra Shaikhrezai, MRCS, Karen McLeod, MD, Brodie Knight, FRACP, and Mark H. D. Danton, MD

Department of Cardiac Surgery and Department of Cardiology, Royal Hospital for Sick Children (Yorkhill), Glasgow, United Kingdom

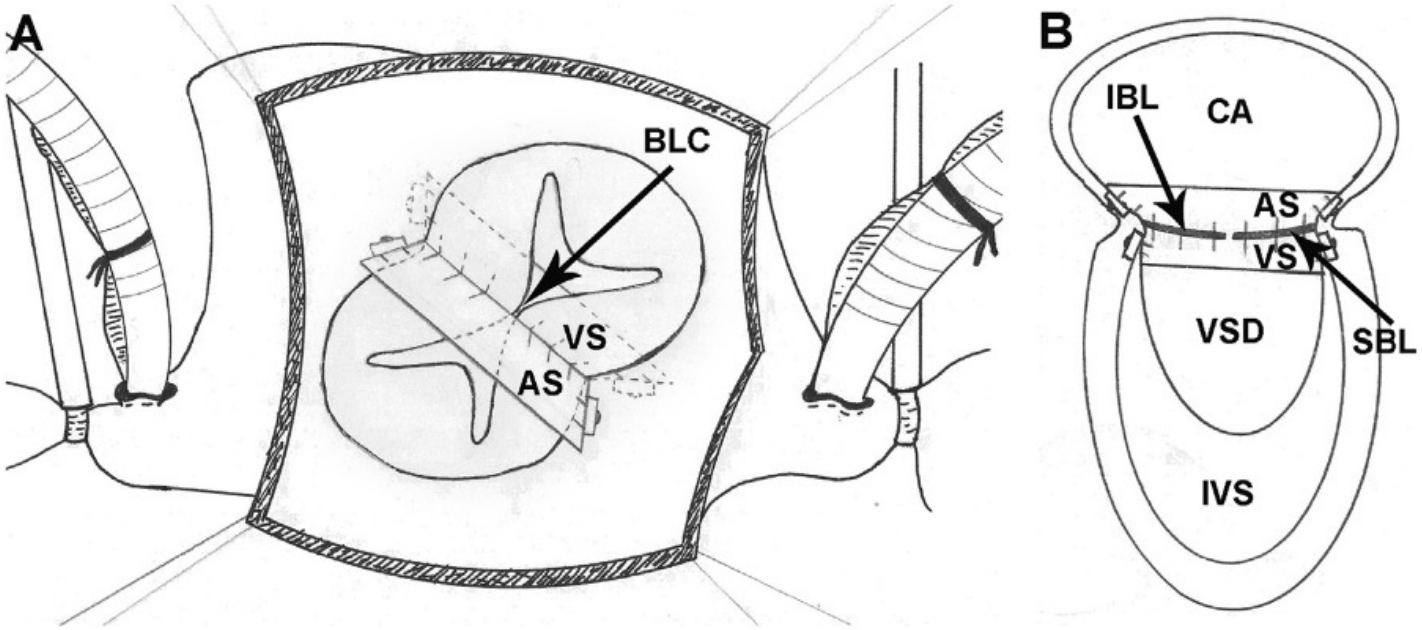

Ann Thorac Surg 2015;100:1124–5

Two-Strip Technique to Repair Common Atrioventricular Valve Regurgitation in Single-Ventricle Palliation

- Modification of repair technique of common atrio-ventricular defect.
- Identify line of septation on bridging leaflets
- Central annular dimension (*L*)
- Ventricular and Atrial strips
  - 5mm x *L* -5
  - Fixed auto-pericardium
- Left and Right cleft closure
- No annuloplasty

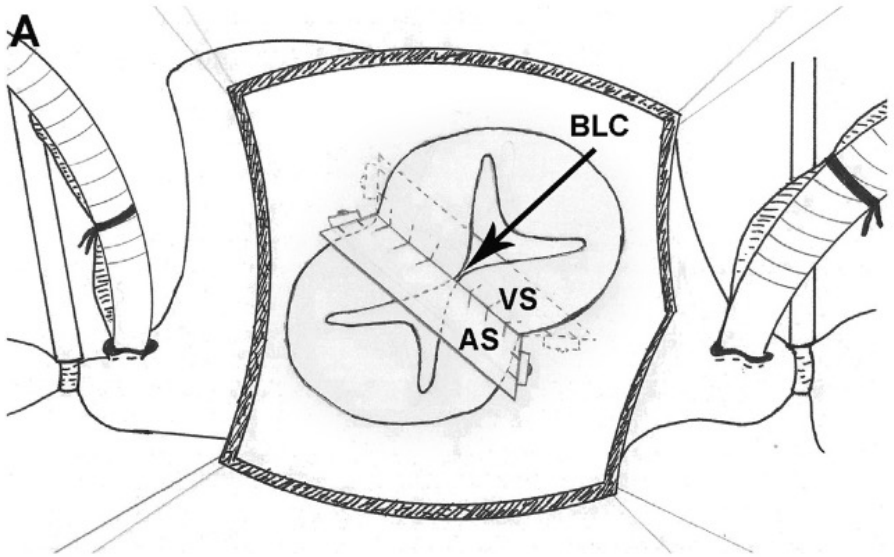

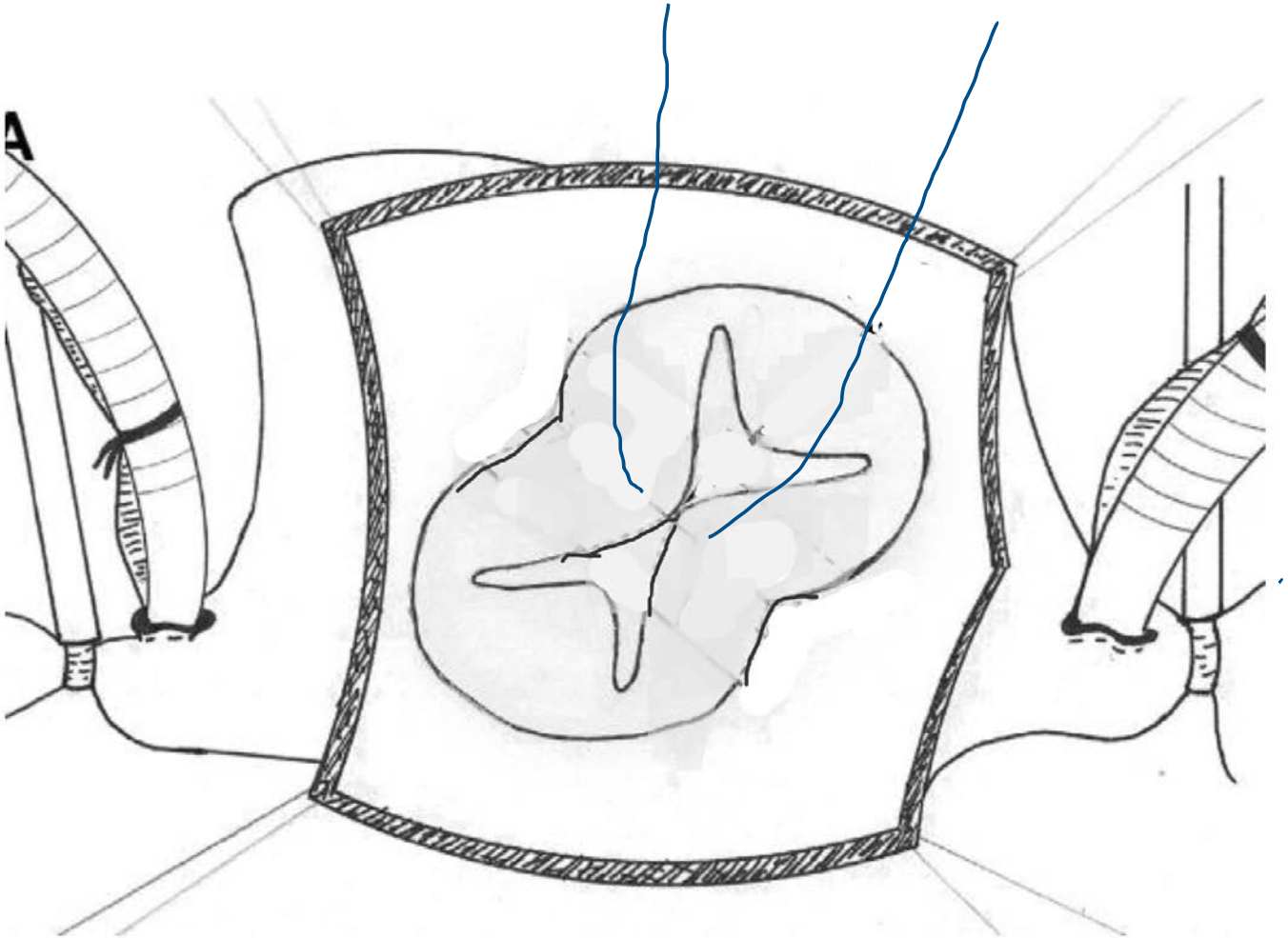
A

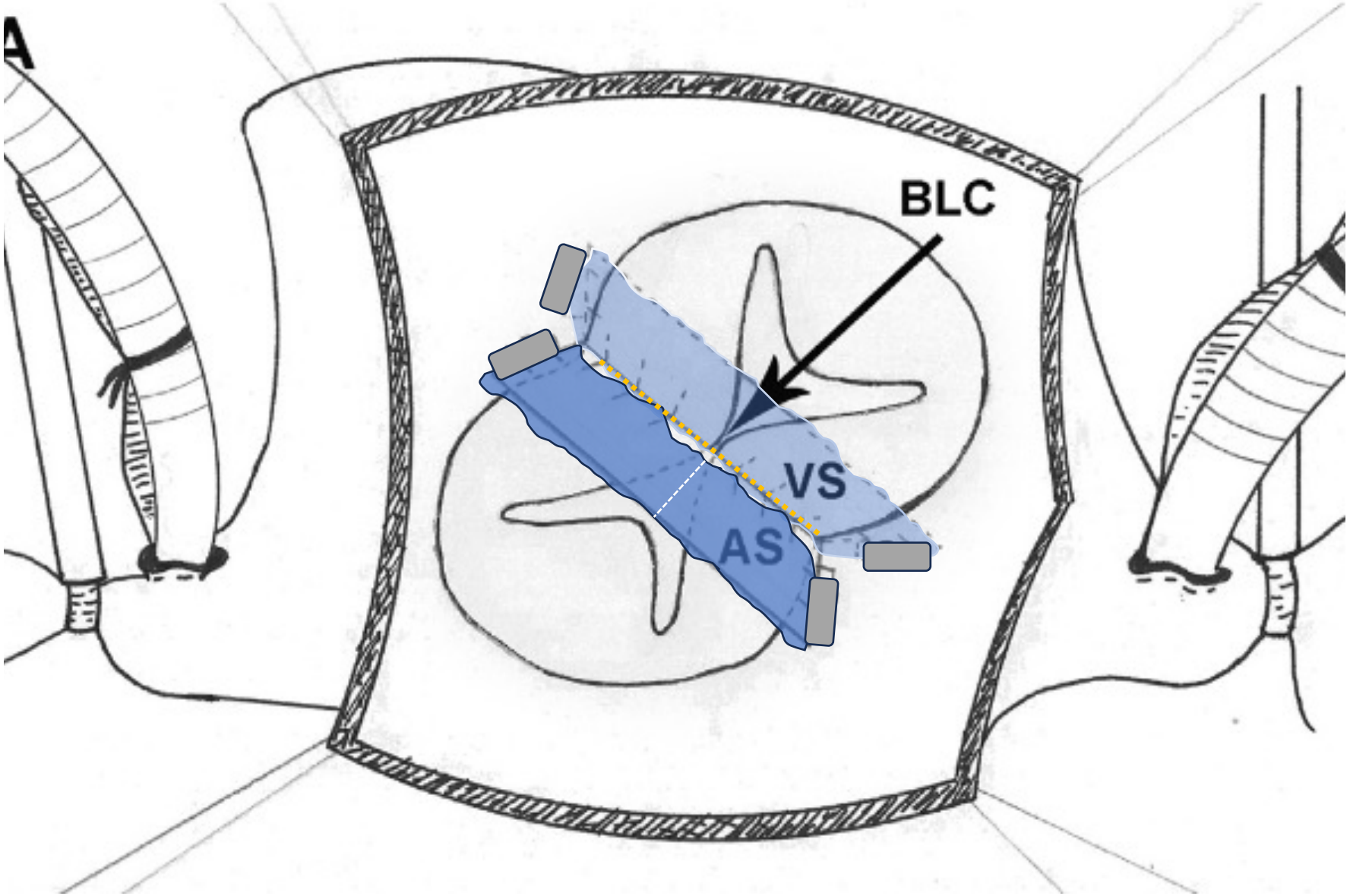
A
BLC
VS
AS

Sagittal section

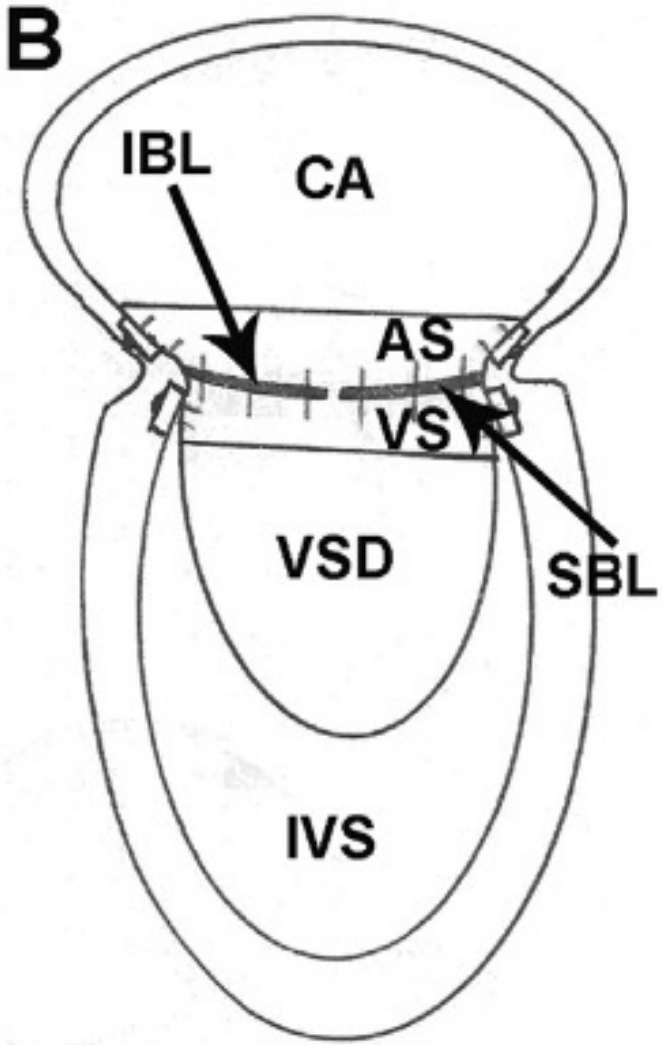

Sagittal section

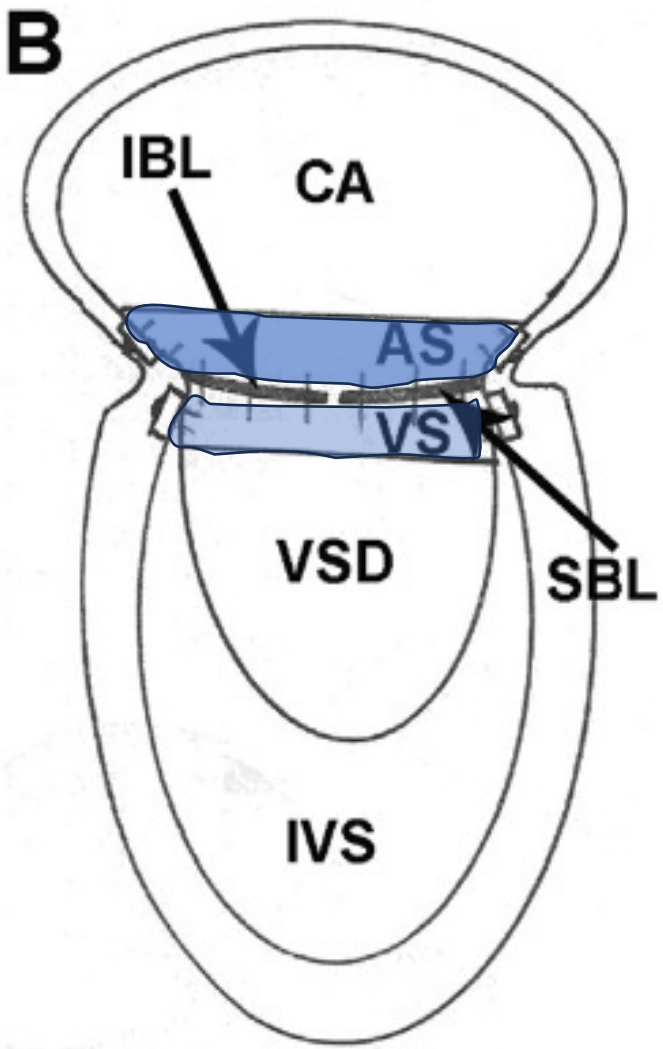

Sagittal section

Supported Bridging leaflets
above and below the valvular plane

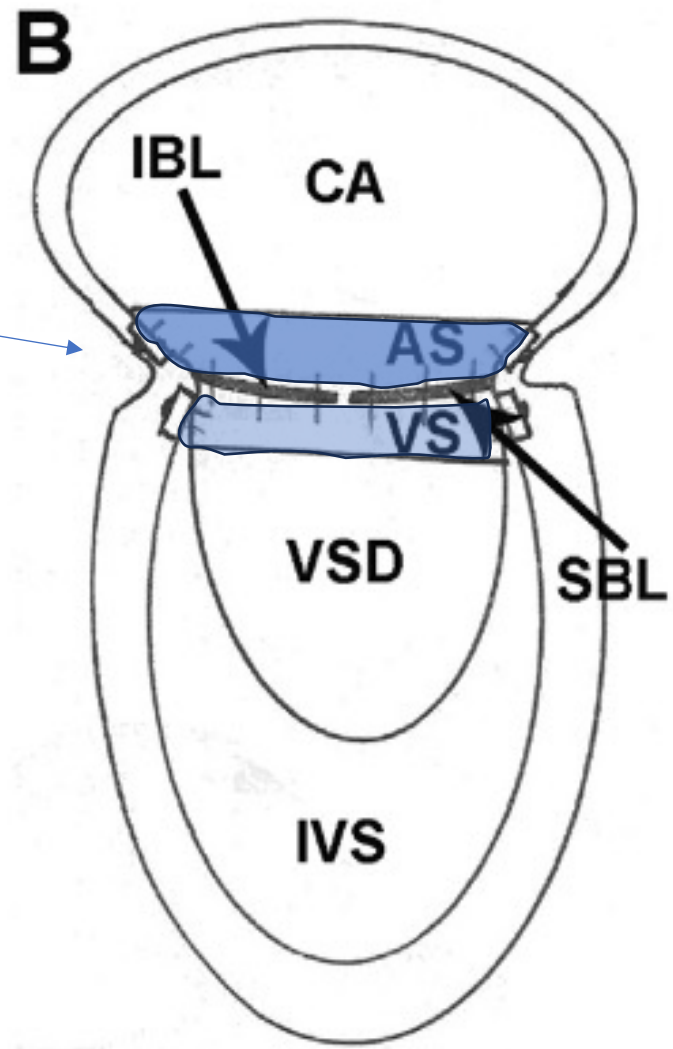

Sagittal section

Supported Bridging leaflets above and below the valvular plane

Restores the leaflets to the annular plane

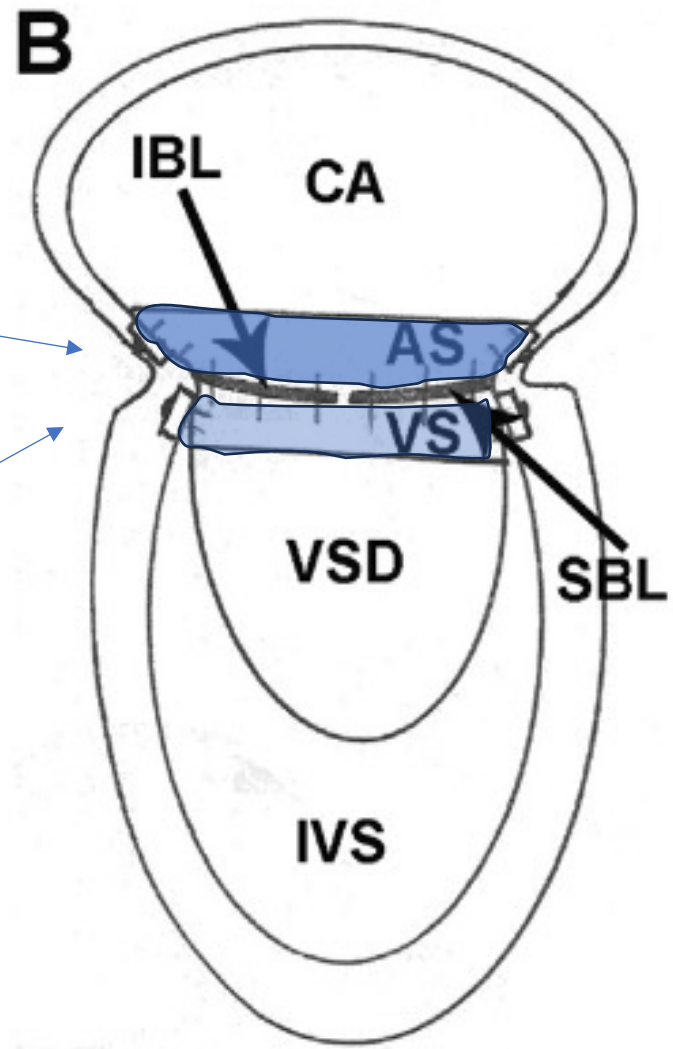

Sagittal section

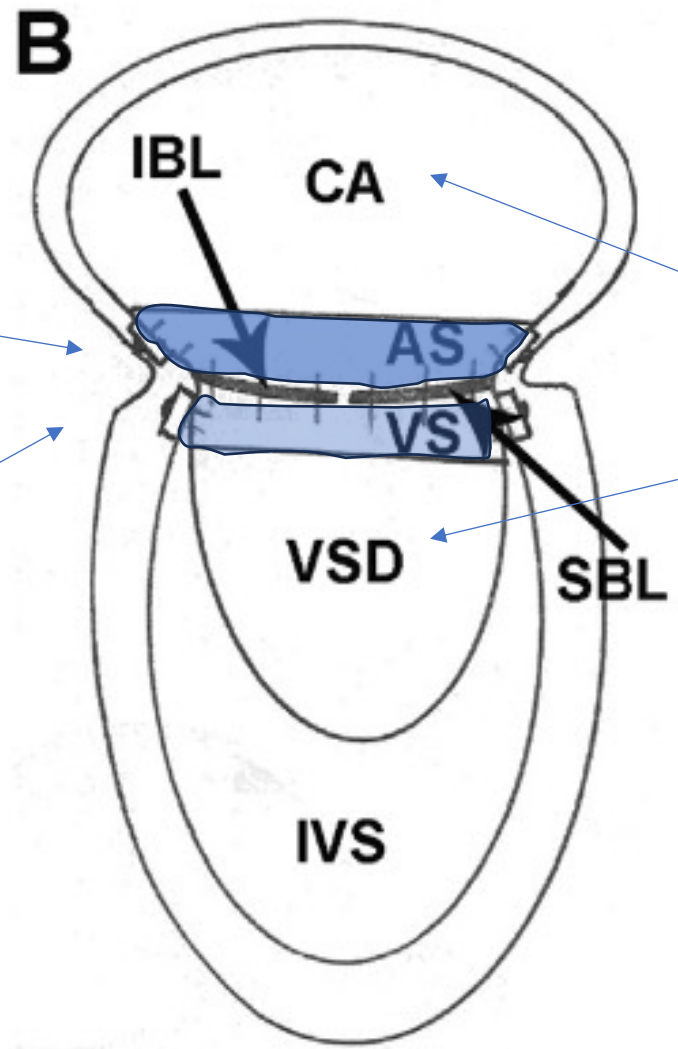

Supported Bridging leaflets above and below the valvular plane

Restores the leaflets to the annular plane

Unobstructed communication at atrial and ventricular level

Kawashima procedure

- Construction of left and right Glenn
- Antegrade Pulmonary artery flow maintained
  - Central PA development
  - Mitigation of arterio-venous malformations

- Good functional result
- Discharged home day 9

Unobstructed VSD flow

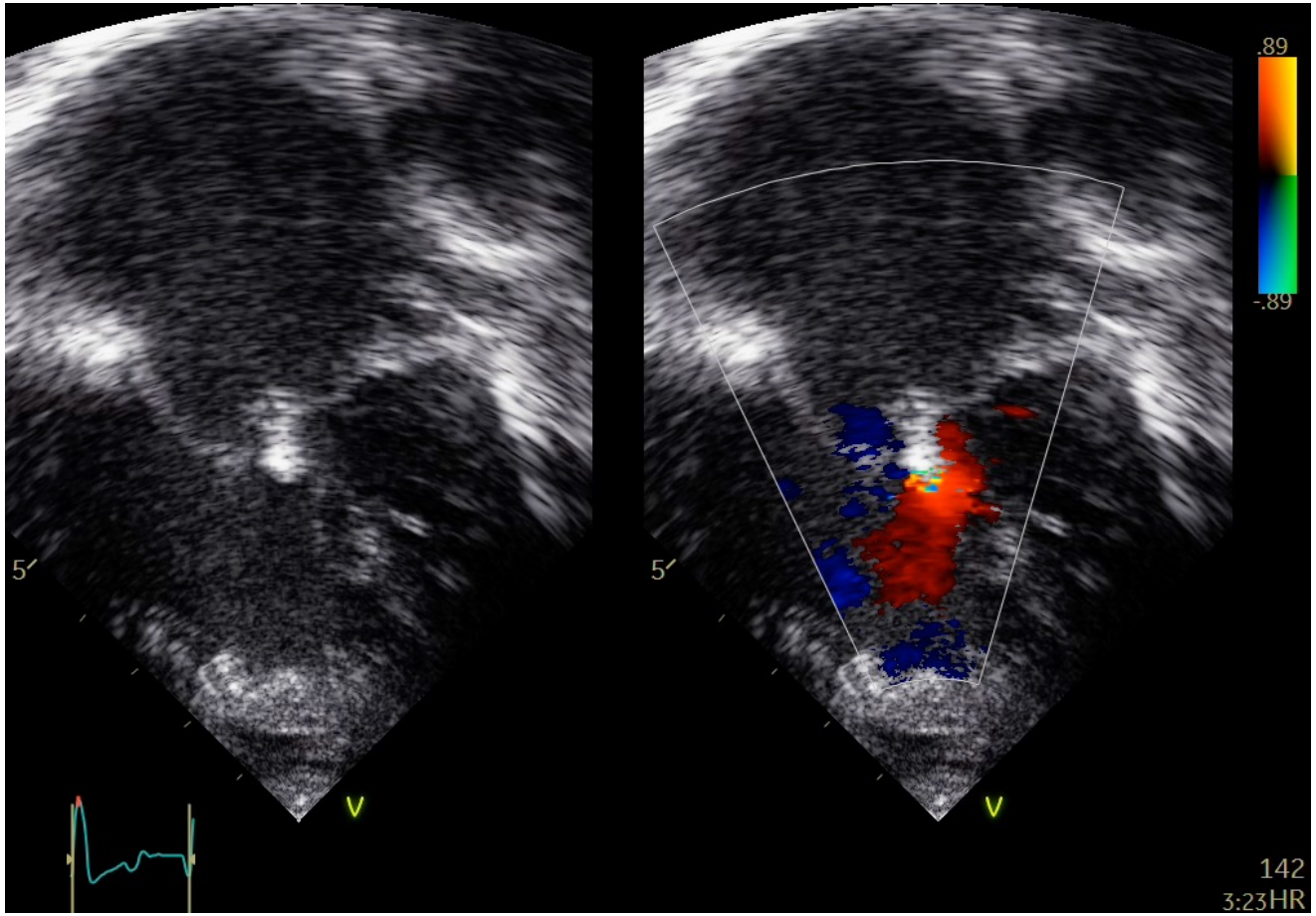

AV valve function

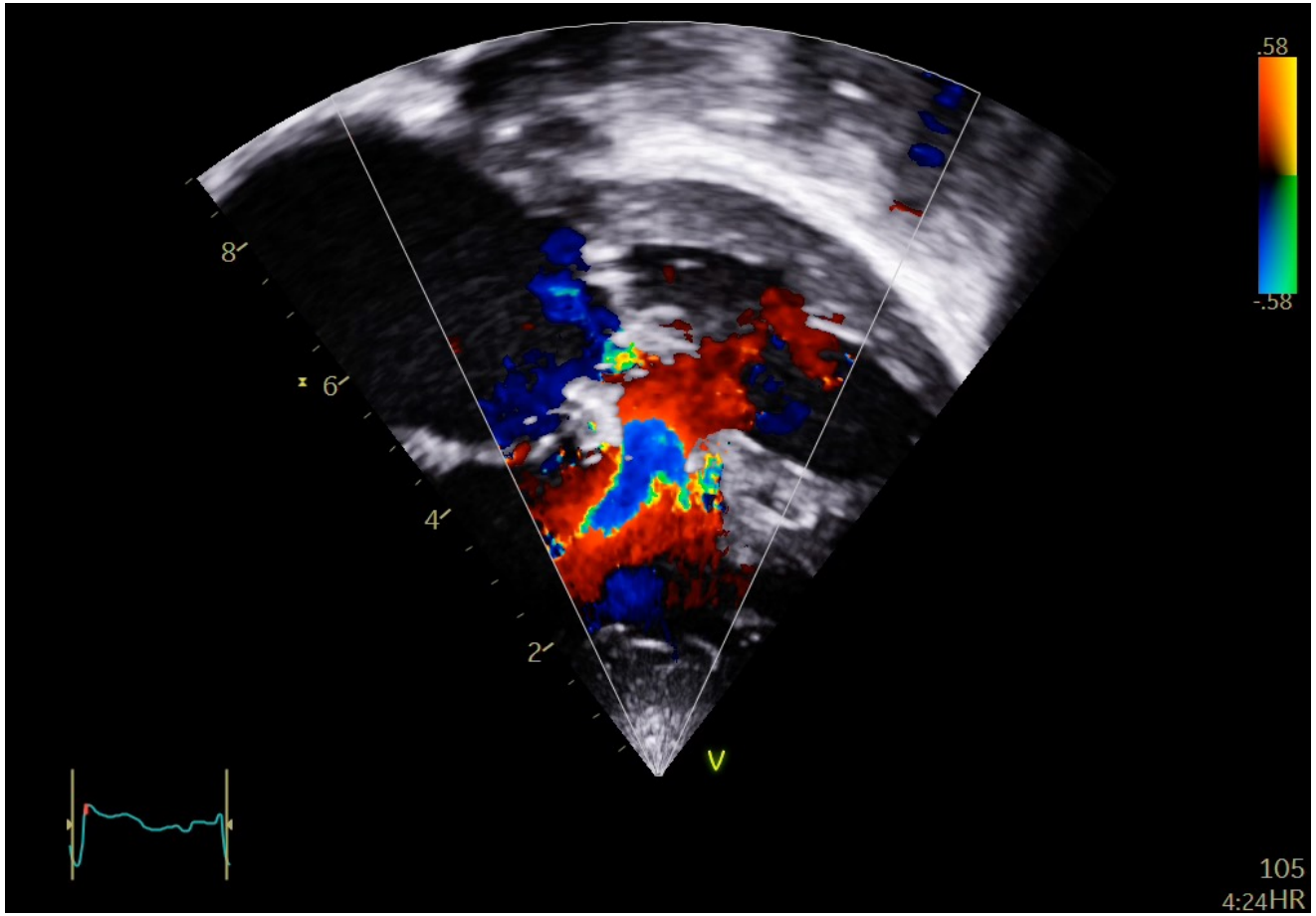

Alignment of inflow to corresponding ventricle

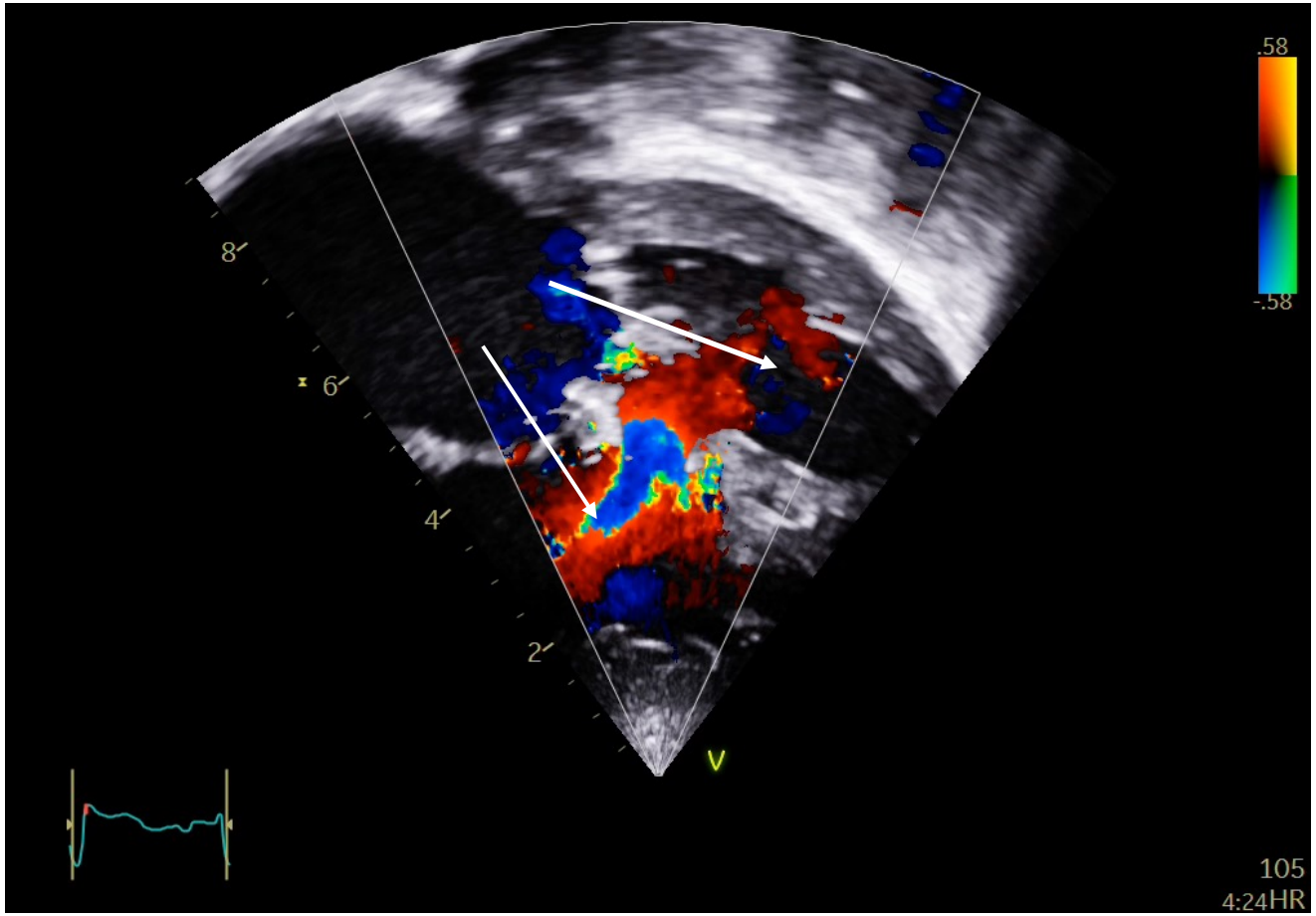

Left Glenn flow

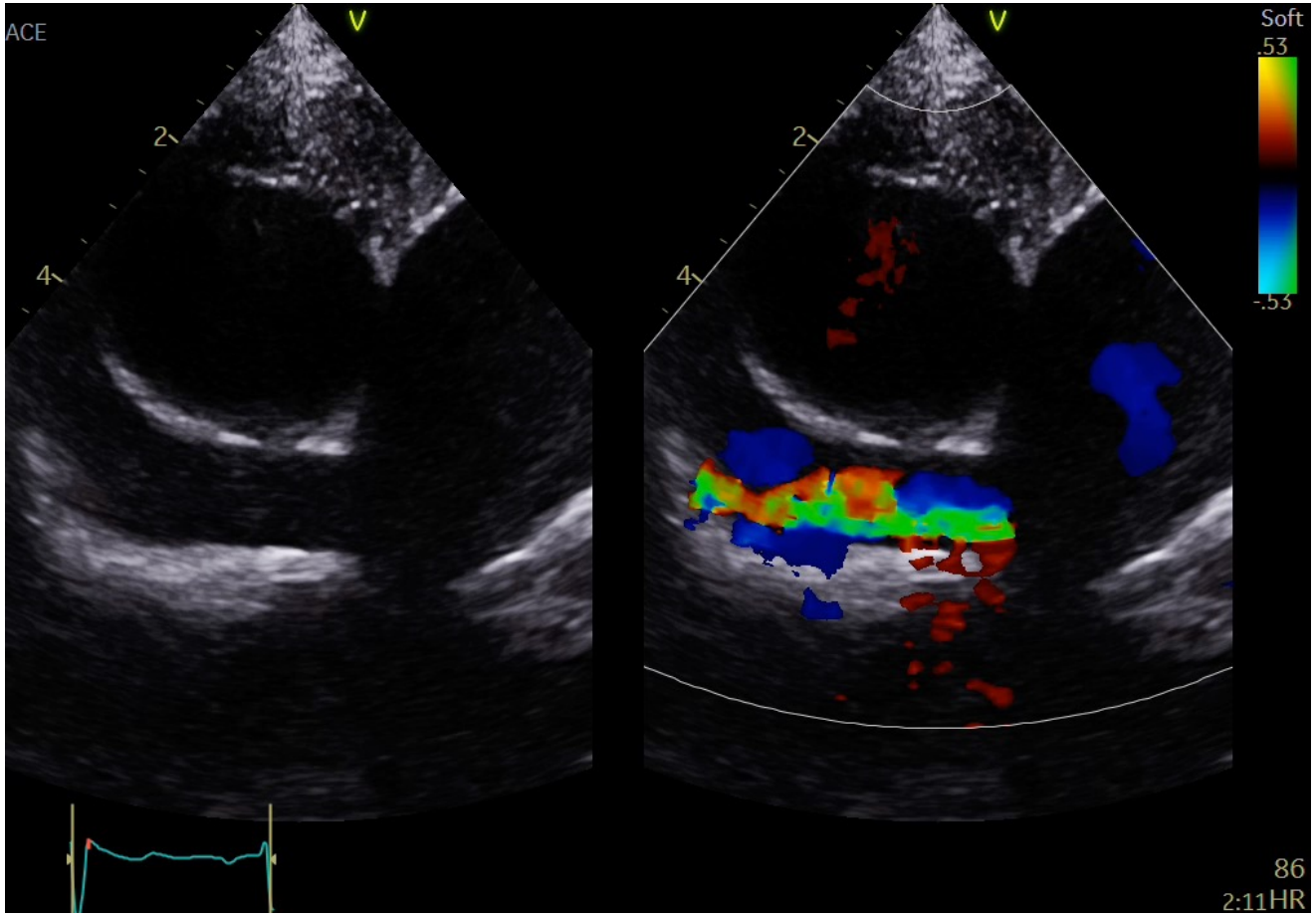

Right Glenn flow

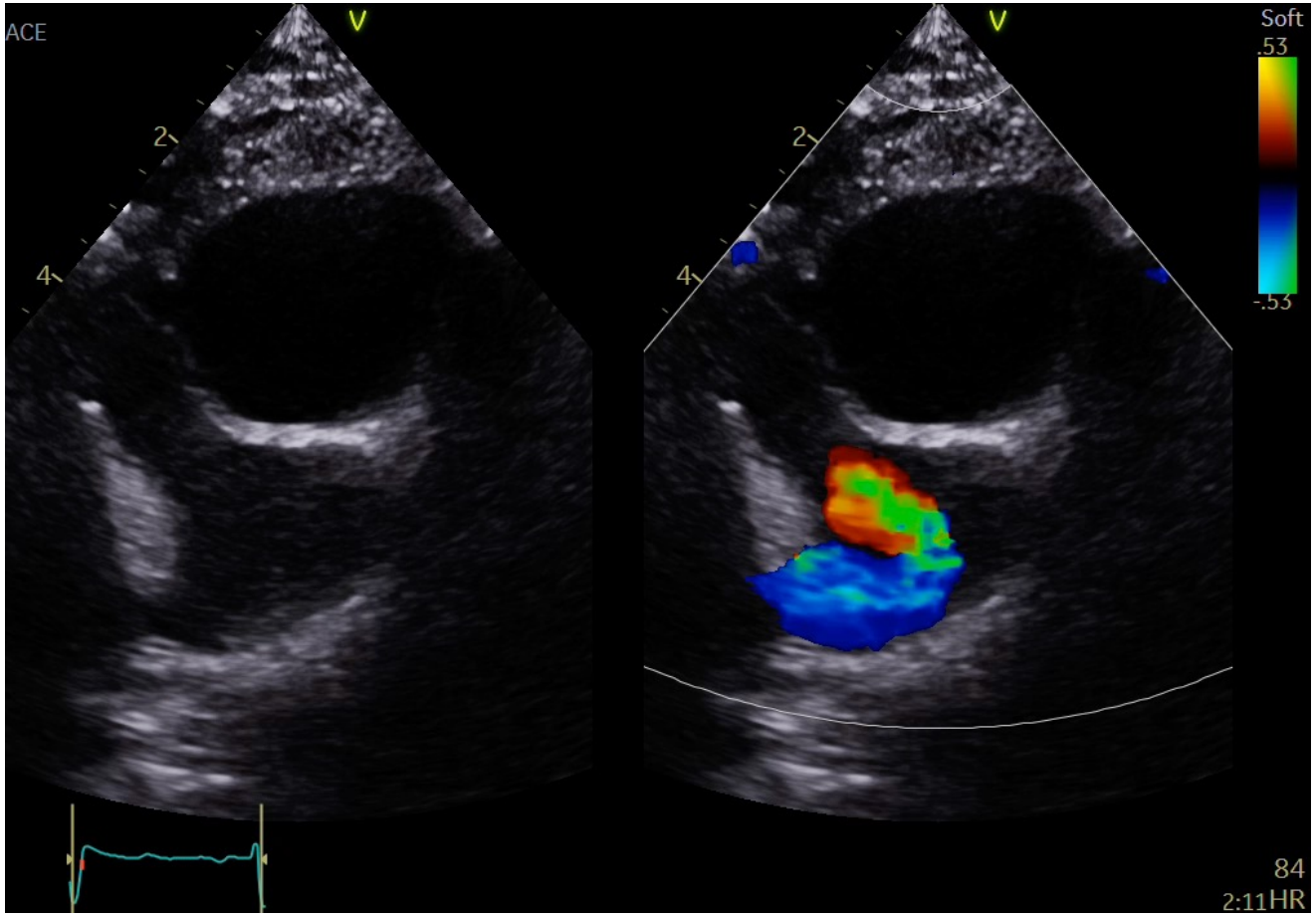

Clinical update

- December, 2023
- 9 years old
- Generally well, active
- No further interventions
- Arterial Saturations at rest = 92%
- CPET and Catheter evaluation
- ± Completion of Total cavo-pulmonary connection (hepatic)

Recent evaluation Dec, 2023 (9 years post-op)

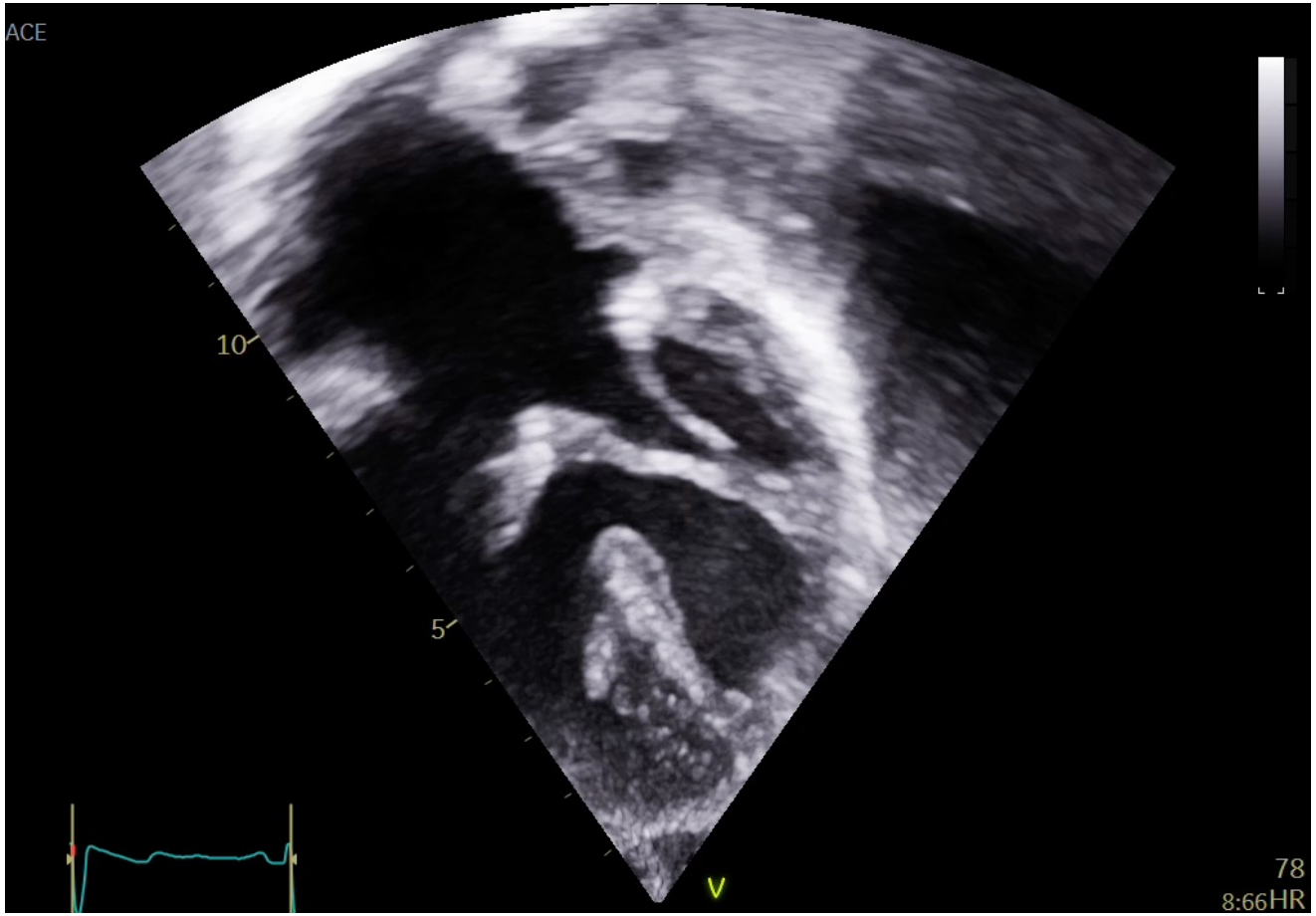

Recent evaluation: valve leaflets en-face

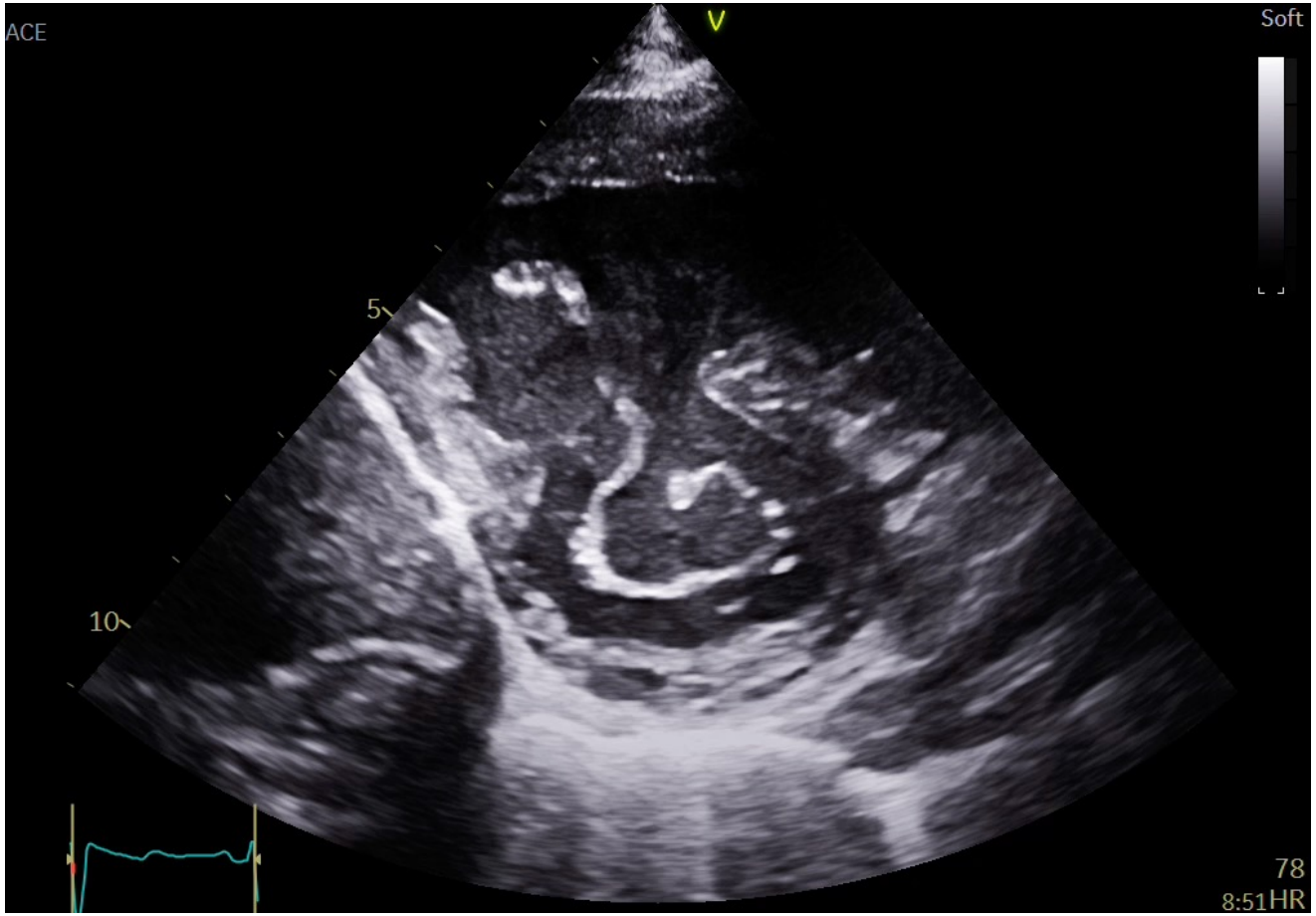

Unobstructed VSD, good AV valve function

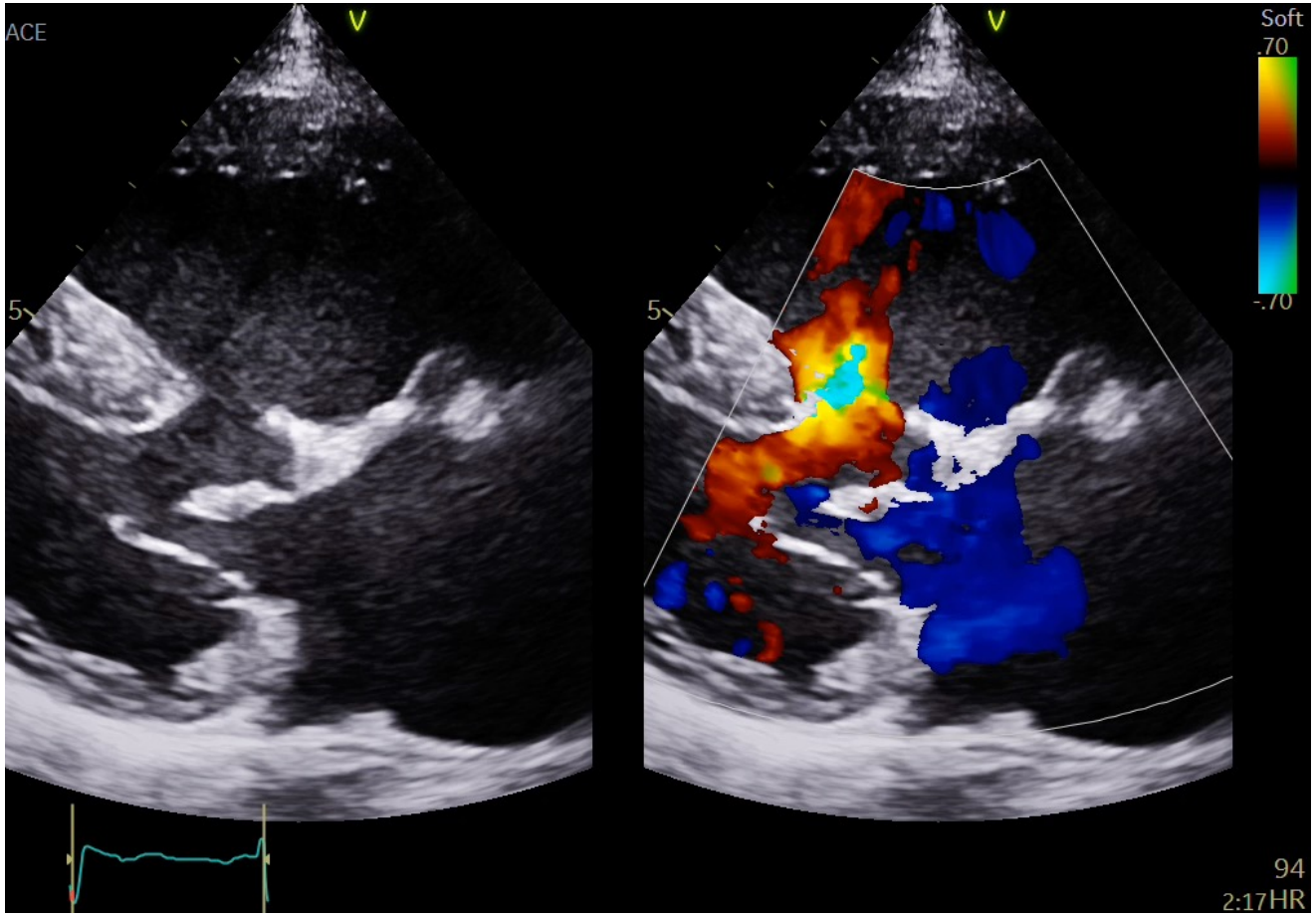

Summary

- 2-strip technique borrows the surgical design for repair of complete atrio-ventricular septal defect for application in single ventricle palliation with common AV valve
- It has provided excellent, stable valve function
- Unobstructed atrial and ventricular communication
- Single intervention
- Patient who initially had v. guarded prognosis (hospice) and who remains well at 9 years post-op

Questions

- Initial management and timing of surgical intervention
  - Control of heart failure, weight gain, reduction in PVR
  - Suitable age/weight for surgery
- Completion of total cava-pulmonary connection
  - Optimize exercise capacity
- Suitability for Bi ventricular repair
  - 3D models

Alternative approaches

Direct suturing of the bridging leaflets along the zone of apposition

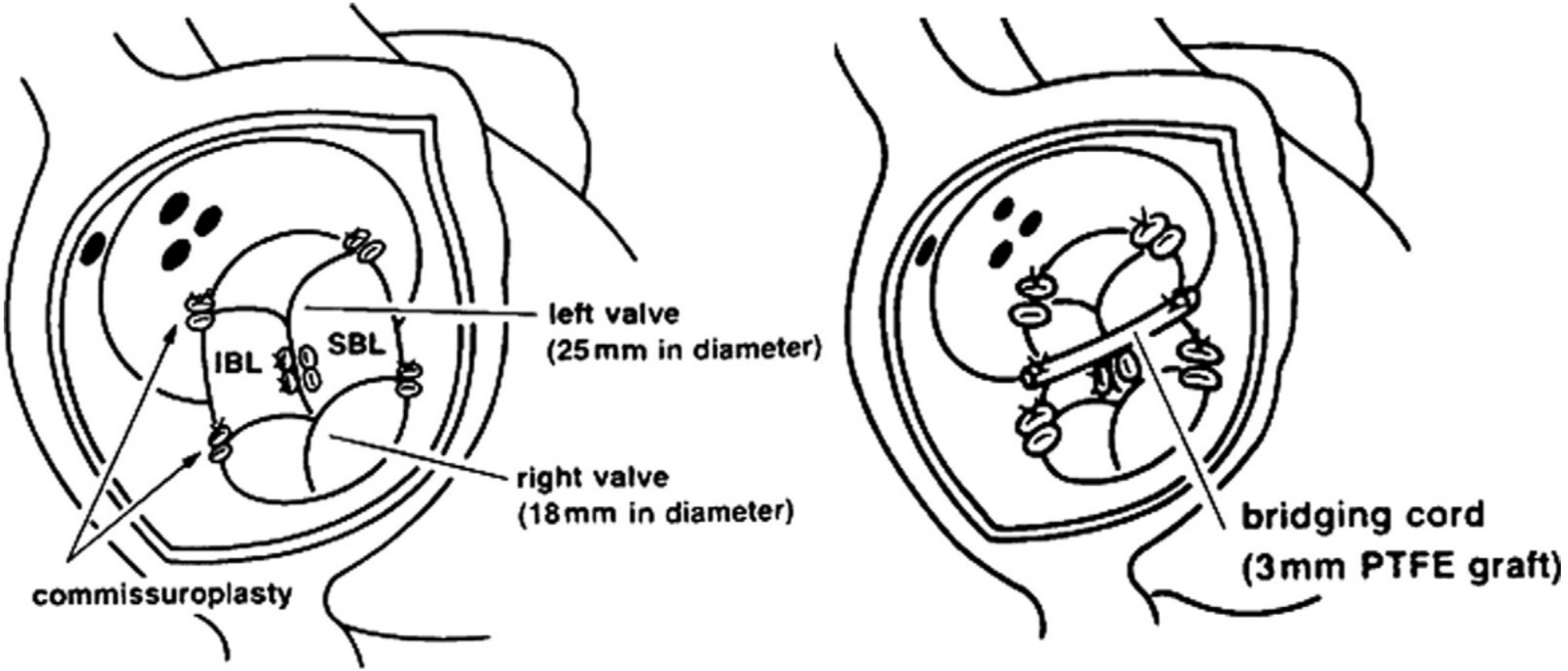

Oku H, Iemura J, Kitayama H, et al: Bivalvation with bridging for common atrioventricular valve regurgitation in right isomerism. Ann Thorac Surg 57:1324-1326, 1994

Edge-to-Edge Repair of Common Atrioventricular or Tricuspid Valve in Patients With Functionally Single Ventricle

Makoto Ando, MD, and Yukihiro Takahashi, MD

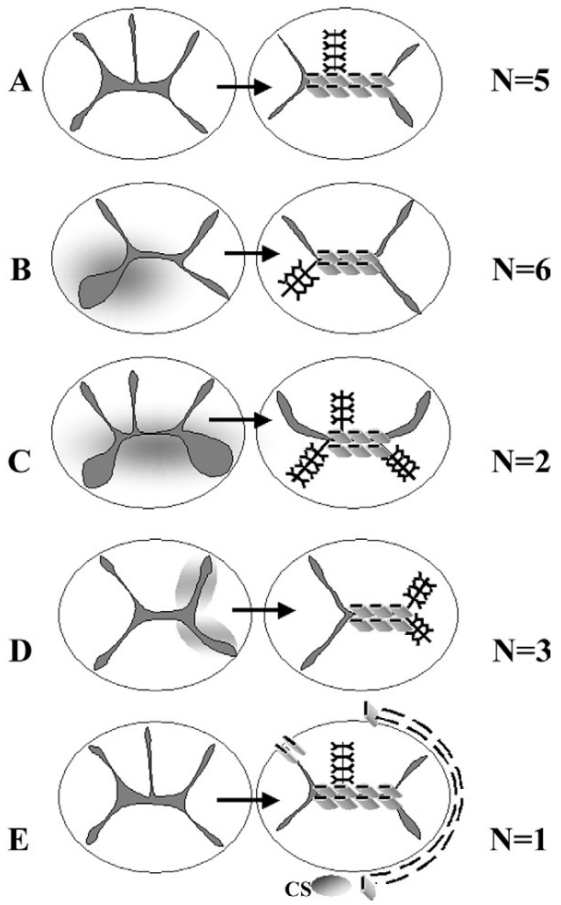

Ann Thorac Surg 2007;84:1571–7

Edge-to-Edge Repair of Common Atrioventricular or Tricuspid Valve in Patients With Functionally Single Ventricle

Makoto Ando, MD, and Yukihiro Takahashi, MD

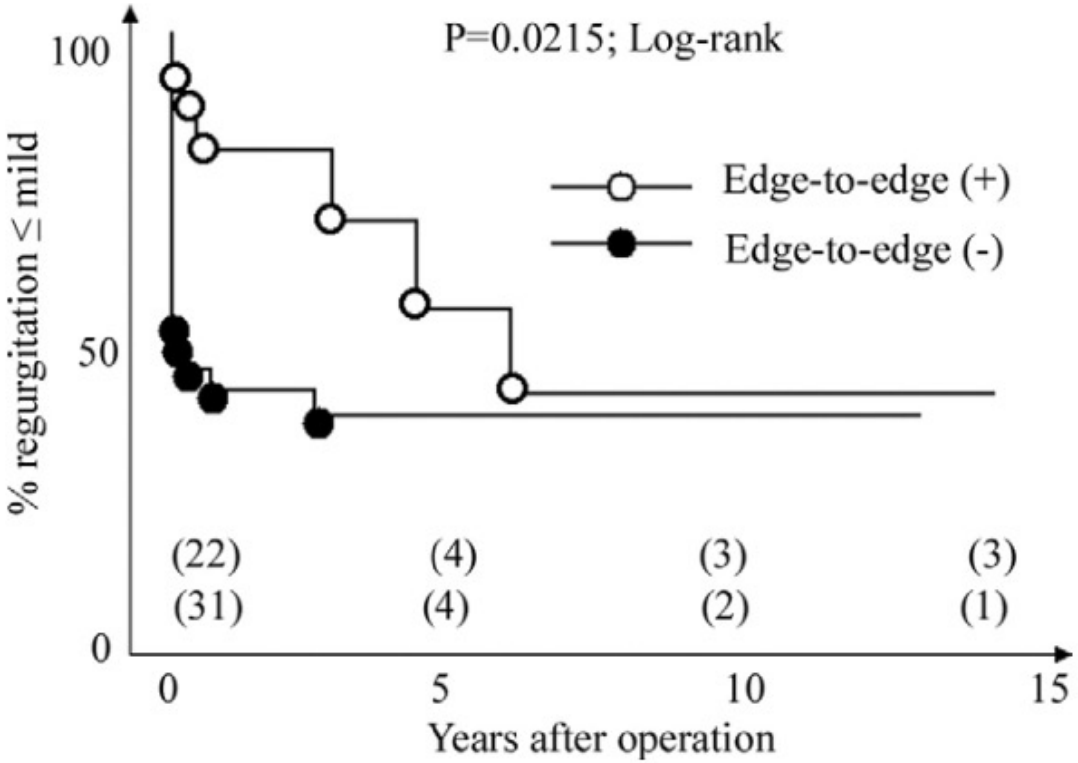

Ann Thorac Surg 2007;84:1571–7

Polytetrafluoroethylene bridge for atrioventricular valve repair in single-ventricle palliation

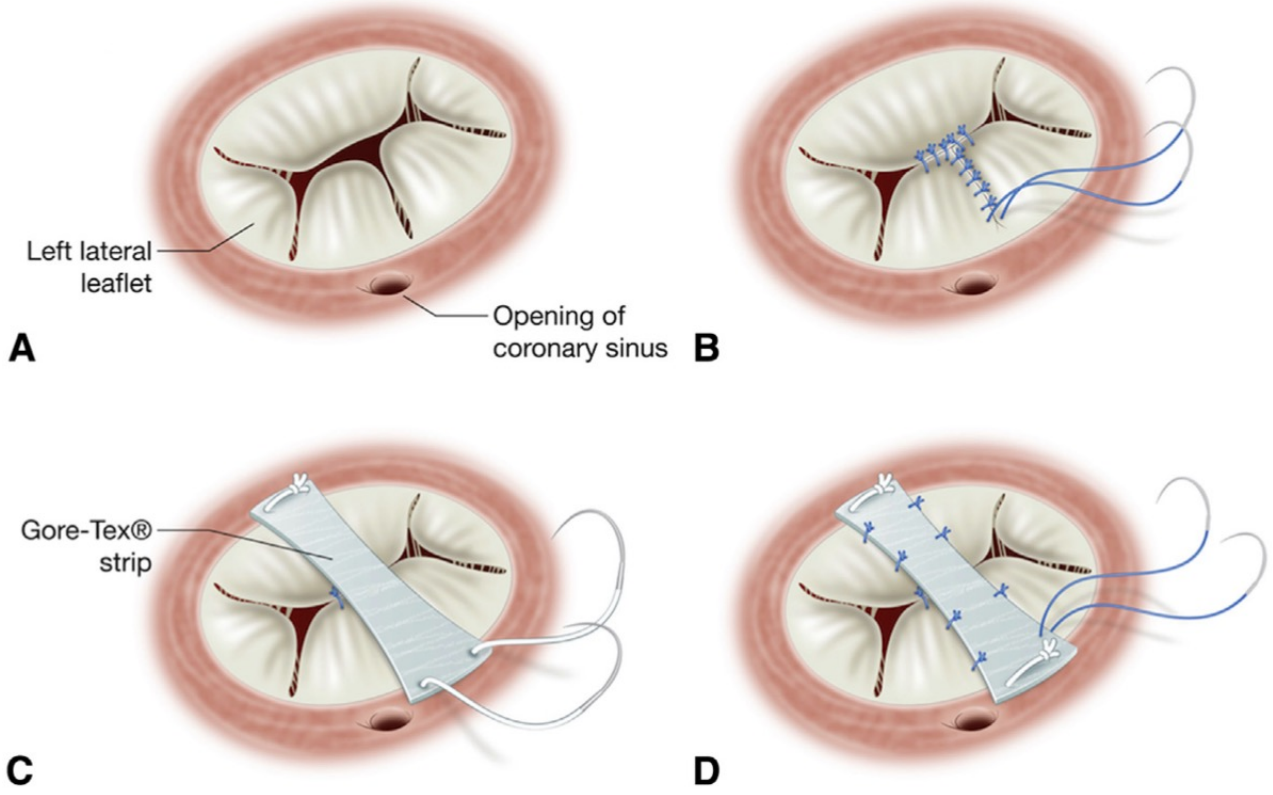

Sughimoto K. et al JTCVS 2014

Increased common atrioventricular valve tenting is a risk factor for progression to severe regurgitation in patients with a single ventricle with unbalanced atrioventricular septal defect

- Moderate to severe regurgitation
  - n=22 (48%)
- Tenting height
  - >6mm
  - 31mm/m^2
  - Annulus-leaflet angle >30^0

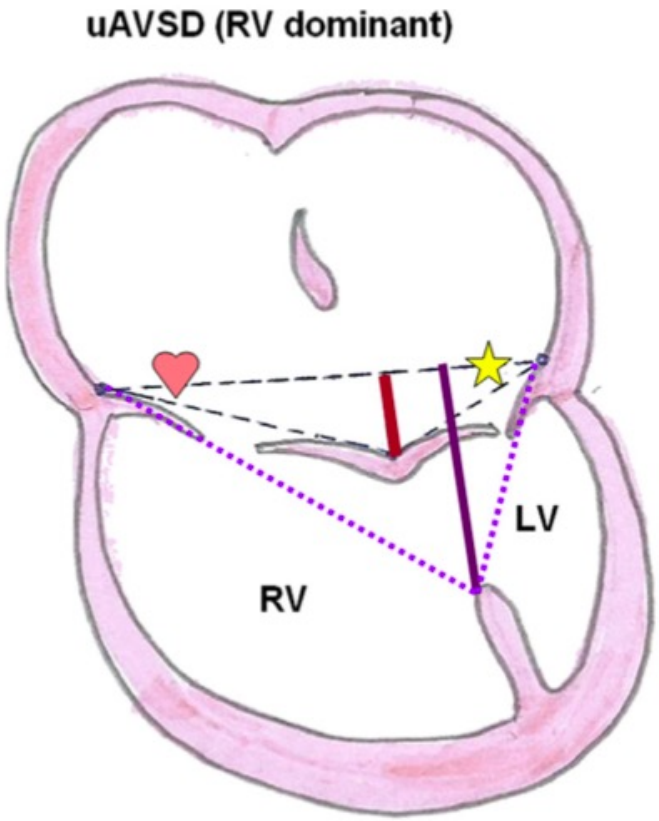

Vijarnsorn C et al. J Thorac Cardiovasc Surg 2014;148:2580-8

Geometric and mechanical advantage

- Bridging leaflets supported in three dimensions

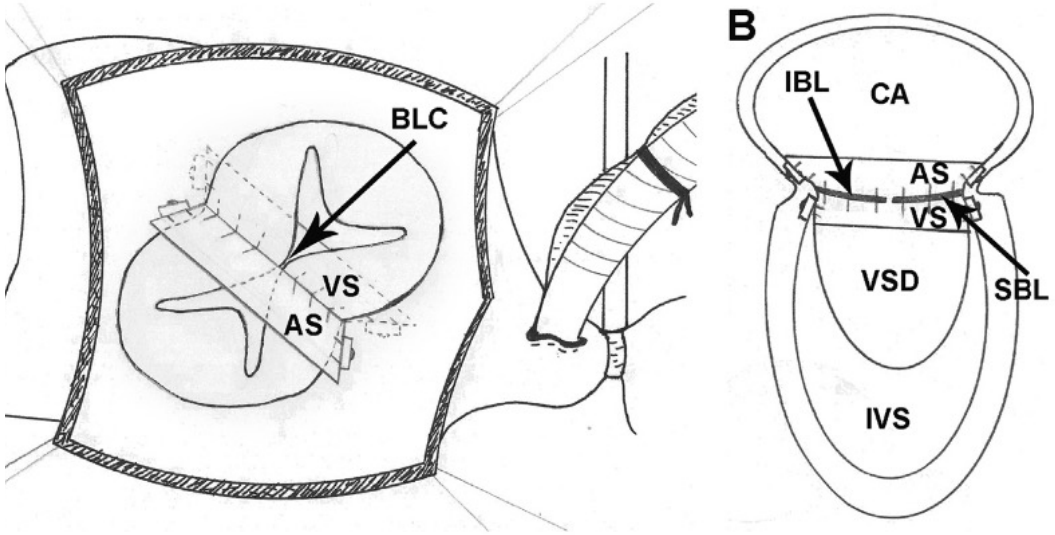

Geometric and mechanical advantage

- Bridging leaflets supported in three dimensions
  - Septation axis.

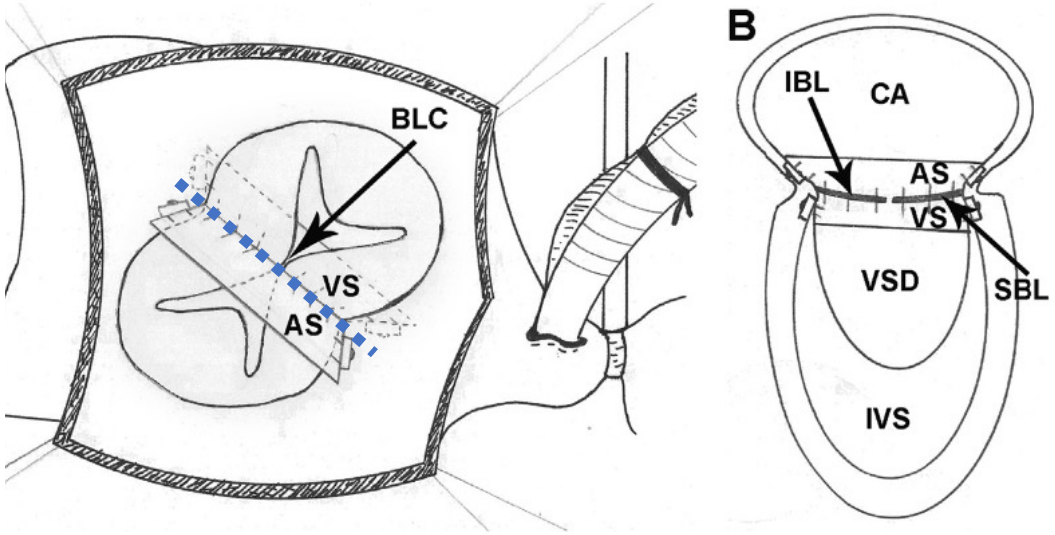

Geometric and mechanical advantage

- Bridging leaflets supported in three dimensions
  - Septation axis
  - Zone of apposition

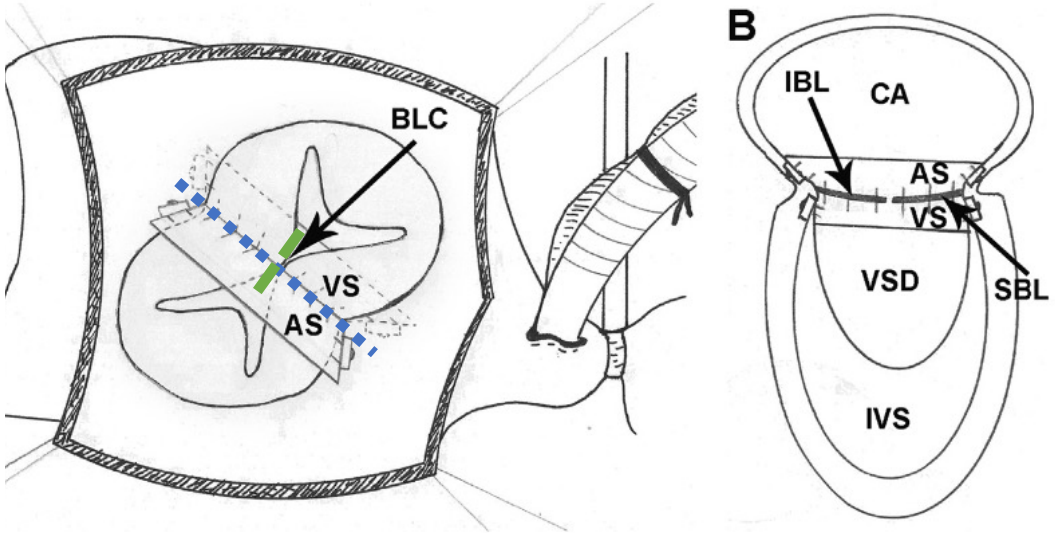

Geometric and mechanical advantage

- Bridging leaflets supported in three dimensions
  - Septation axis
  - Zone of apposition
  - Atrial-ventricular

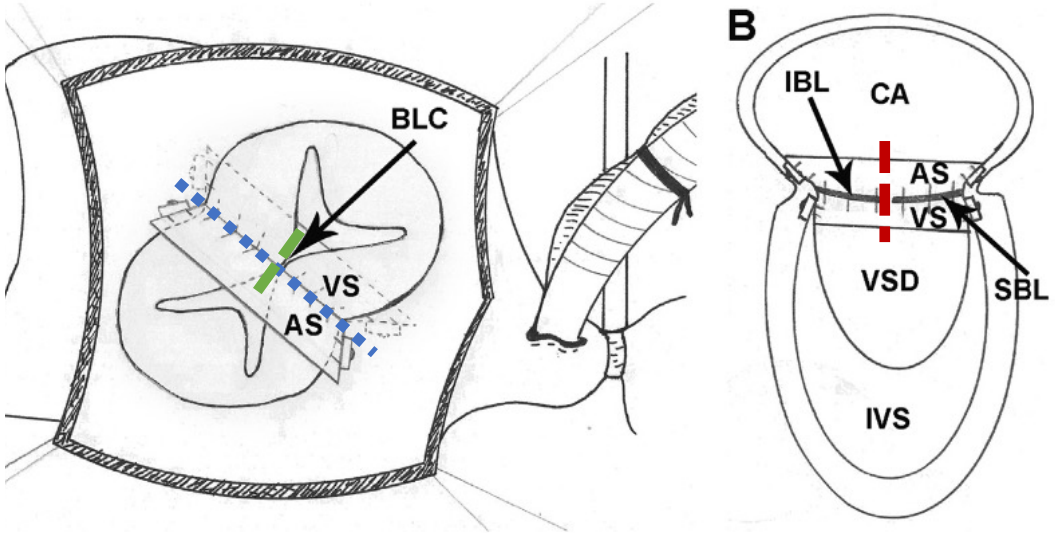

Geometric and mechanical advantage

- Reduces the tenting angle restoring the Bridging leaflets to the annular plane
- Provides leaflet support above and below the leaflet tissue
- Allows a central ‘annuloplasty’
- Aligns inflow to respective ventricle

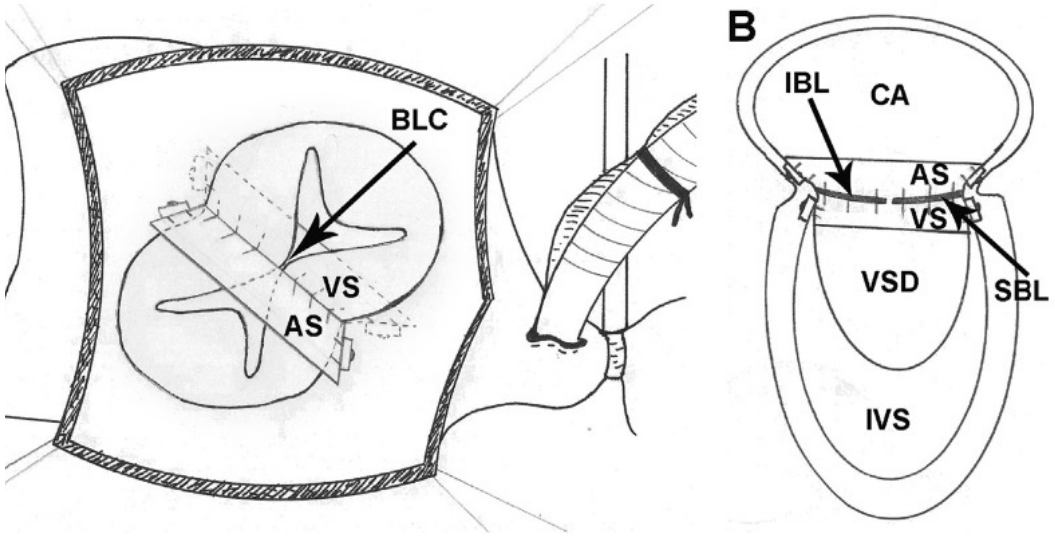

Septation in complex AVSD

- Is it physiologically suitable
  - Non-apex forming LV
  - Large inlet VSD
  - LV/RV Inlet angle

- Is it anatomically possible
  - Straddling chords of atrioventricular valve
  - Septation of the common atrium:
    - bilateral SCVs, dominant Left SVC/ pulmonary veins across mid-line
  - VSD remote from Aorta

Feasibility of Biventricular Repair in Right Dominant Unbalanced Atrioventricular Septal Defect: A New Echocardiographic Metric to Refine Surgical Decision-Making

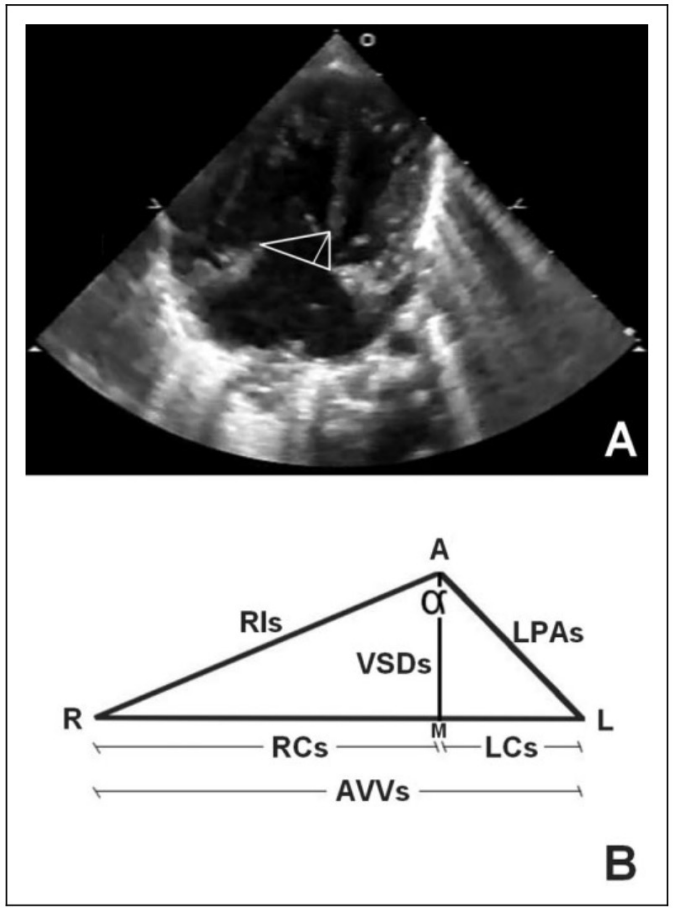

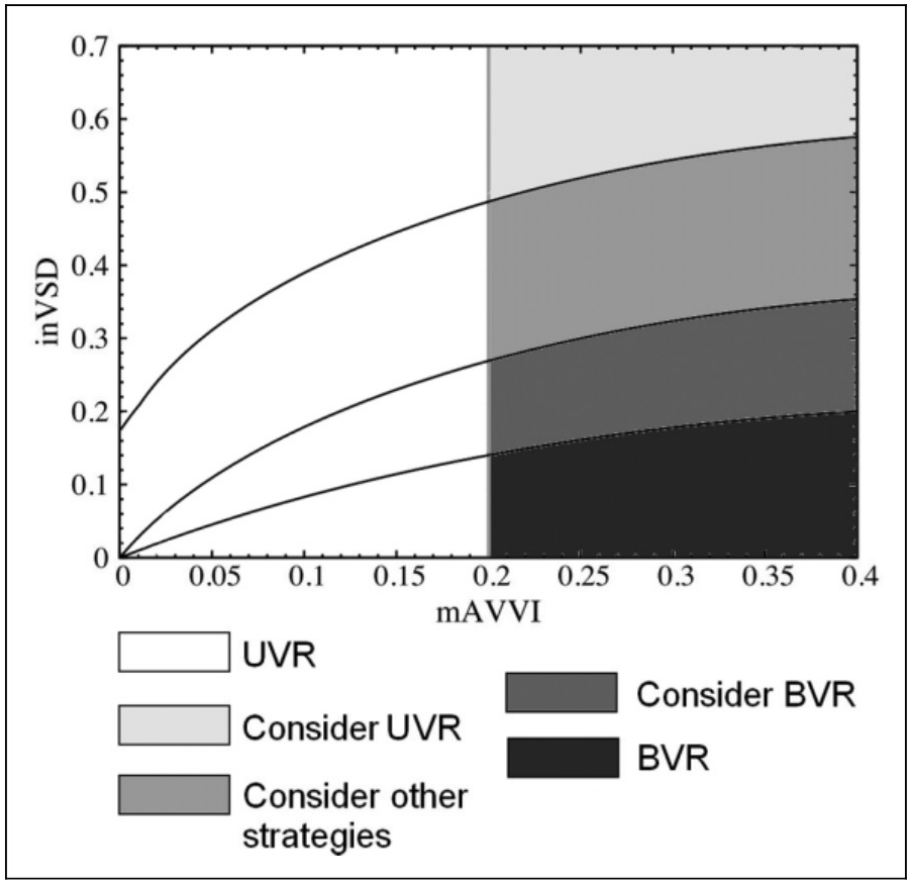

Lugones, I. Et al. World Journal for Pediatric and Congenital Heart Surgery 2017, Vol. 8(4) 460-467

Feasibility of Biventricular Repair in Right Dominant Unbalanced Atrioventricular Septal Defect: A New Echocardiographic Metric to Refine Surgical Decision-Making

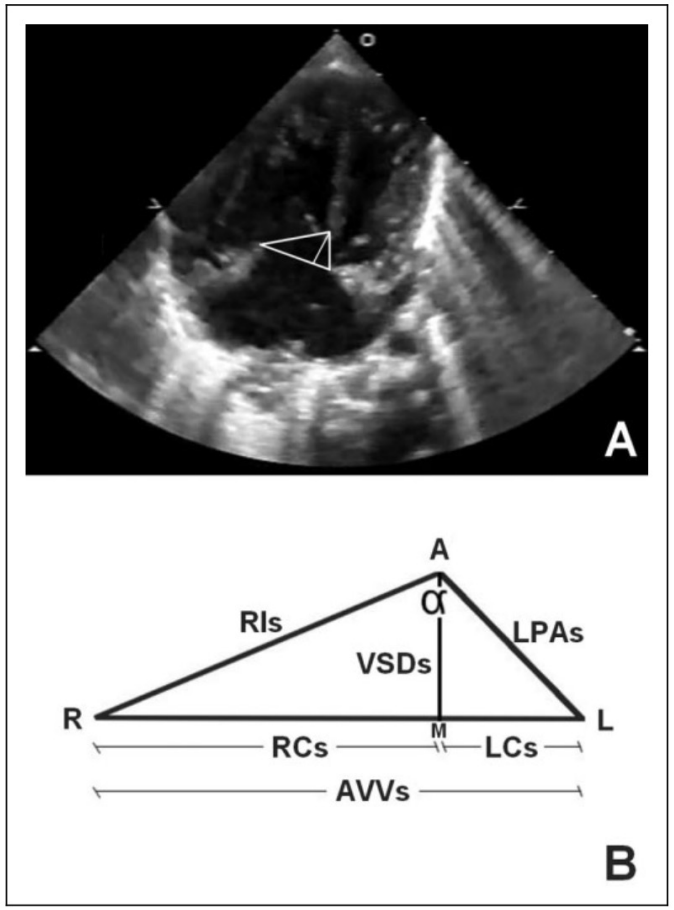

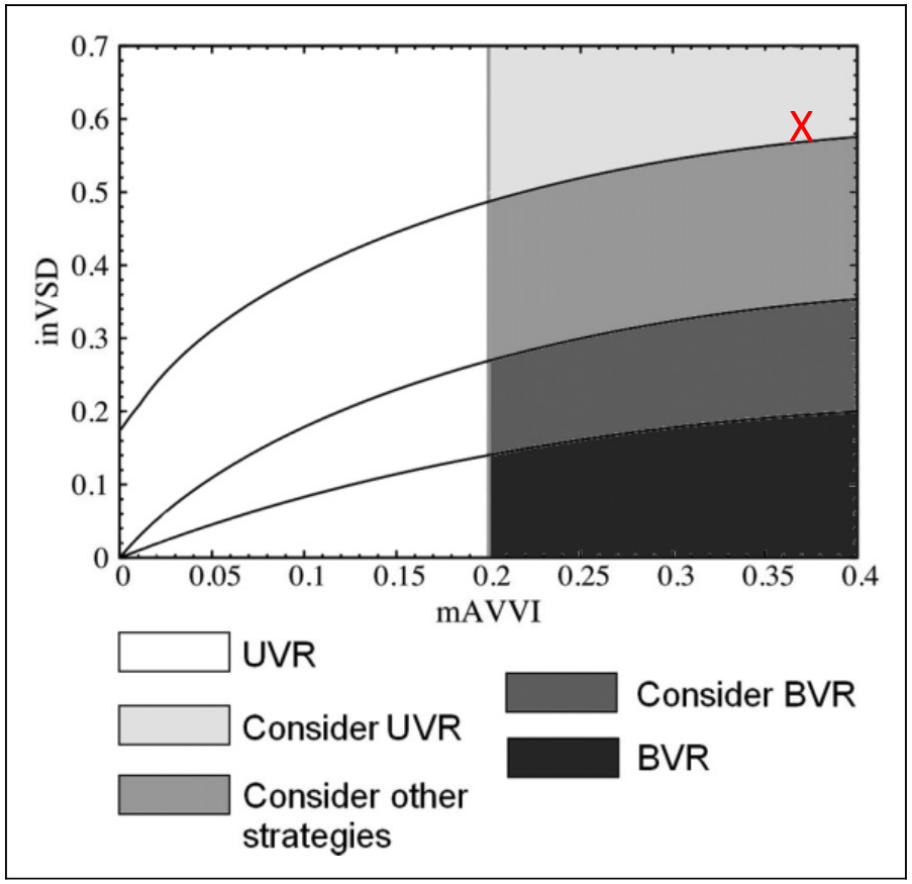

Lugones, I. Et al. World Journal for Pediatric and Congenital Heart Surgery 2017, Vol. 8(4) 460-467

Staged ventricular recruitment and biventricular conversion following single-ventricle palliation in unbalanced atrioventricular canal defects

Check for updates

Nicholas A. Oh, MD,[a,b] Ilias P. Doulamis, MD,[a] Alvise Guariento, MD,[a] Breanna Piekarski, BSN, RN,[a]

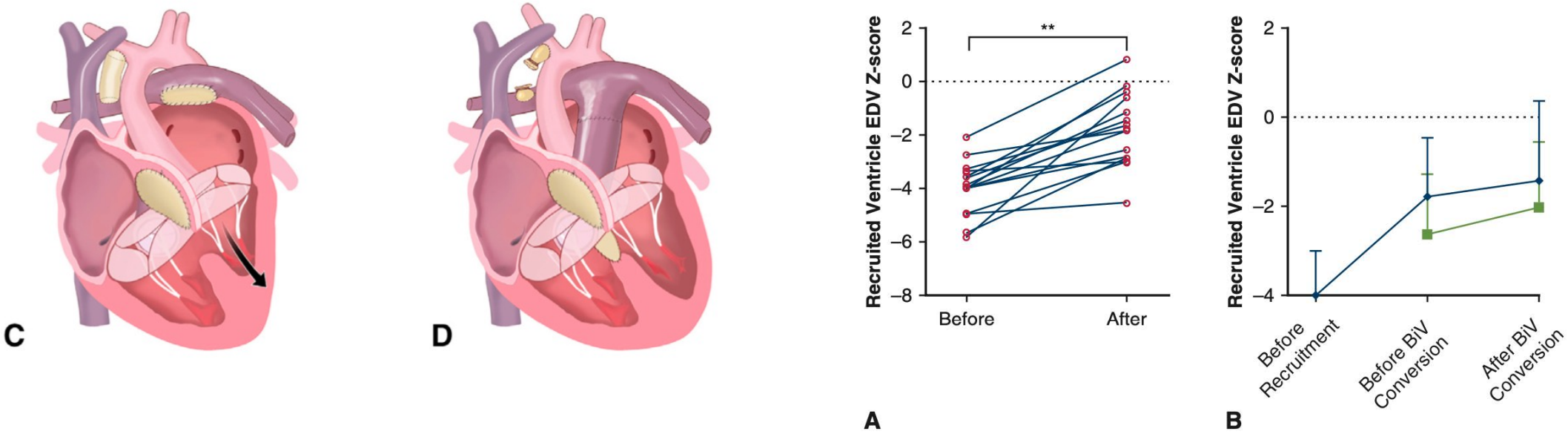

JTCVS Open 2023;13:278-91

Ventricular septation

Aorta in continuity with common atrioventricular valve

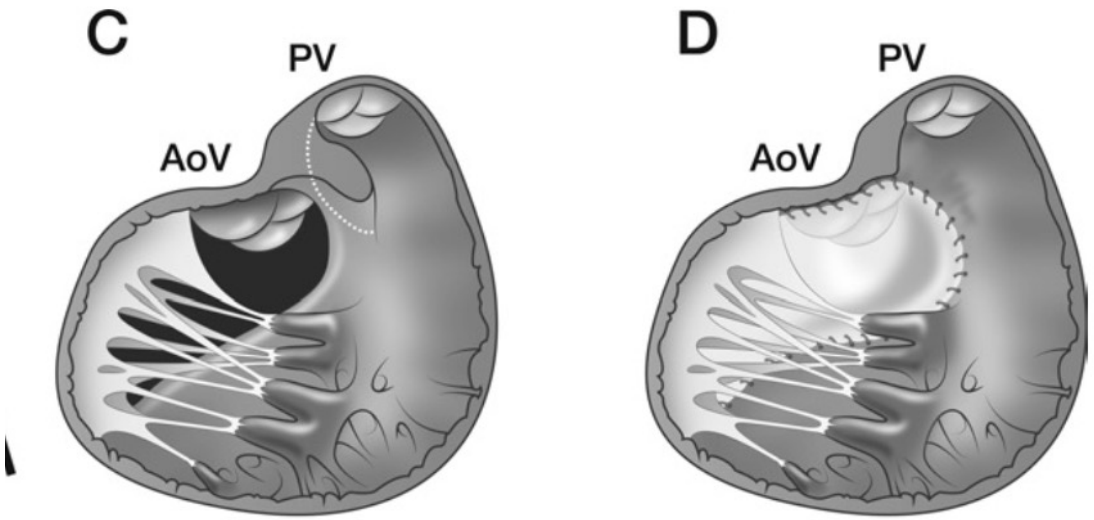

Ong J. et al. Ann Thorac Surg 2012;94:172–8

Remote aorta requiring resection of outlet Septum

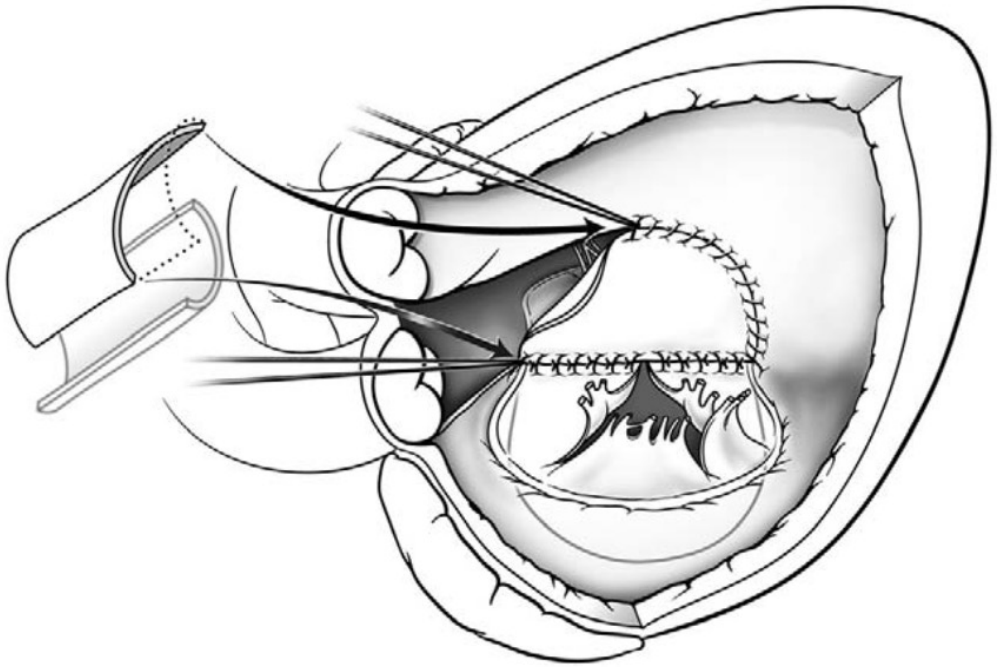

Devaney E.J. et al Ann Thorac Surg 2010;89:537–43

Atrial Septation

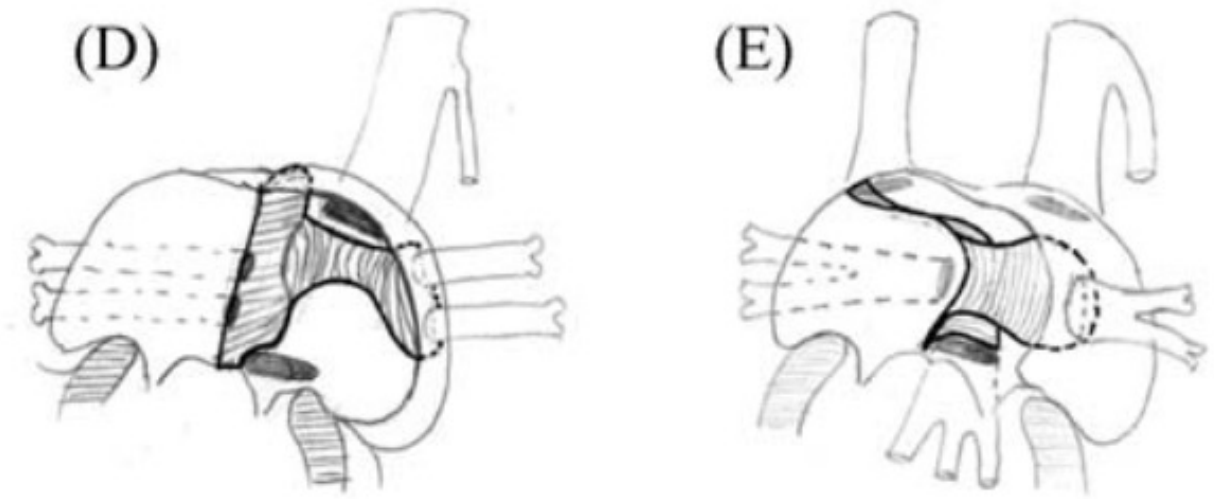

Left atrial isomerism: biventricular repair Vodiskar J. et al European Journal of Cardio-thoracic Surgery 37 (2010) 1259—1263

TGA and cAVSD

Long-term outcomes of single-ventricle palliation for unbalanced atrioventricular septal defects: Fontan survivors do better than previously thought

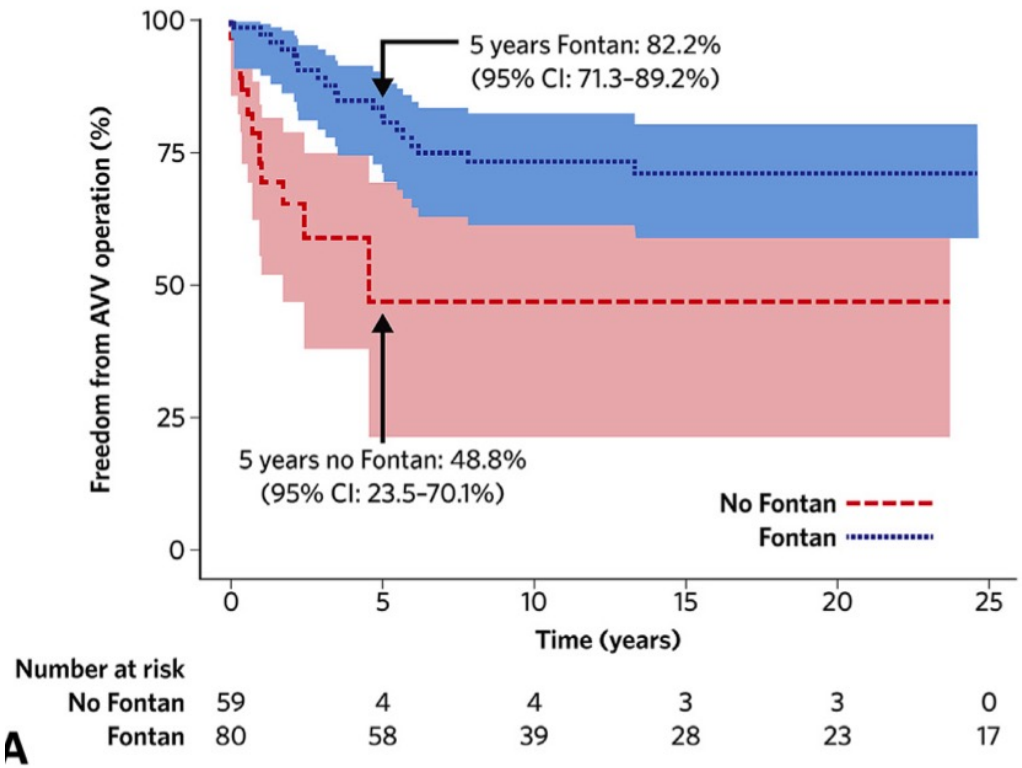

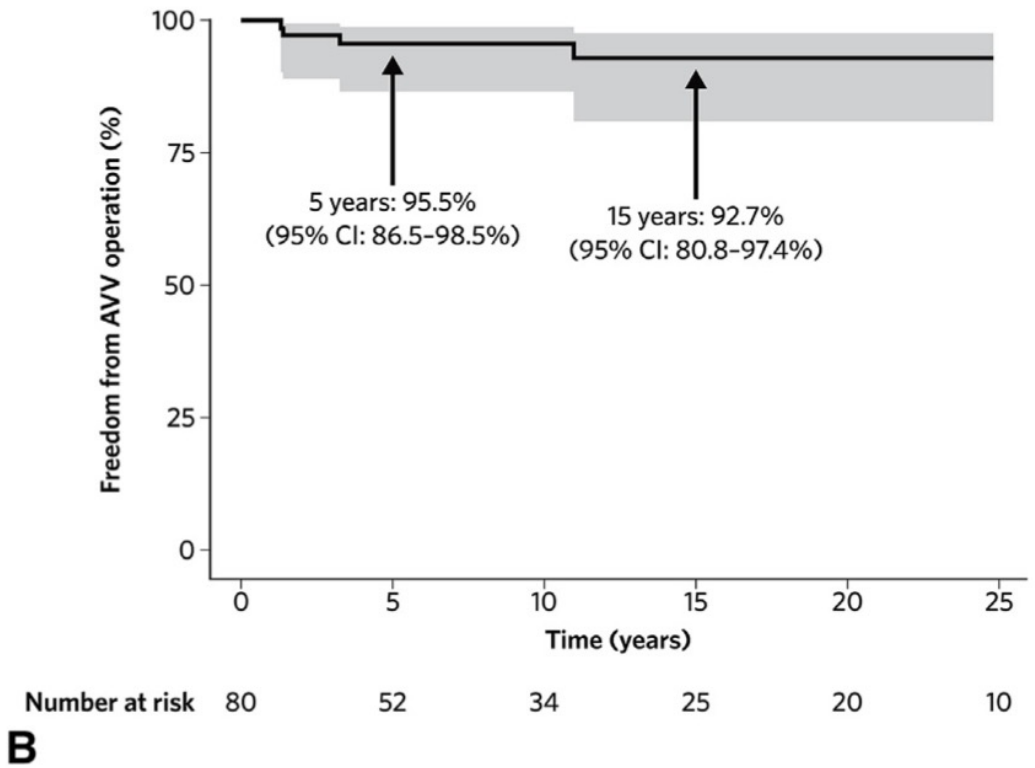

Buratto E. et al J Thorac Cardiovasc Surg 2017;153:430-8

Importance of valve function in SVP

- *”Importantly, we observed that atrioventricular valve (AVV) regurgitation is a major contributor to morbidity and mortality observed in these patients”*
- *“Patients with AVV regurgitation who achieved successful repair had much better outcomes than those with a significant residual regurgitation”*

Buratto E, 2017 Eur J Cardiothorac Surg

In conclusion

- Optimal common atrioventricular valve function is critical in single ventricle palliation
- Two-strip septation of the common atrioventricular valve normalizes valve morphology by restoring ventricular septal support, returning leaflets to the annular plane and stablising the valve in three dimensions
- In complex left atrial isomerism with severe AV regurgitation the technique has provided excellent durable valve function and allowed single ventricle palliation
- Potentially improves inflow alignment to allow ventricular development and biventricular conversion