



Children's Hospital

Case Presentation

Mirella Molenschot

Pediatric (interventional) Cardiologist



University Medical Center Utrecht

Case

66 year old female

Hypertension during pregnancy

Age 55 - hypertension

2013 – moderate Aortic valve stenosis

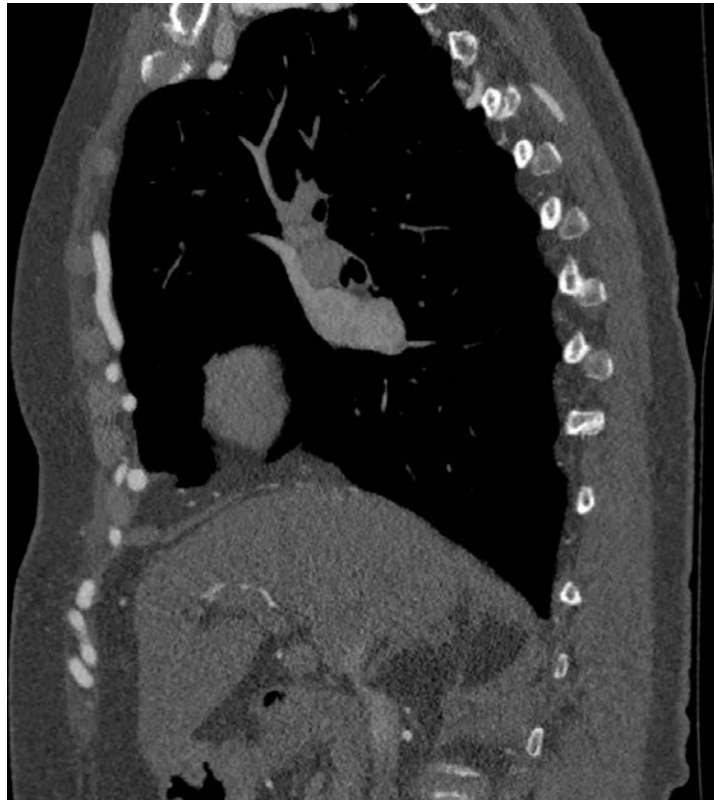2016 - CAG PCI mid LAD

2018 - severe Aortic valve stenosis . CAG: no coronary disease

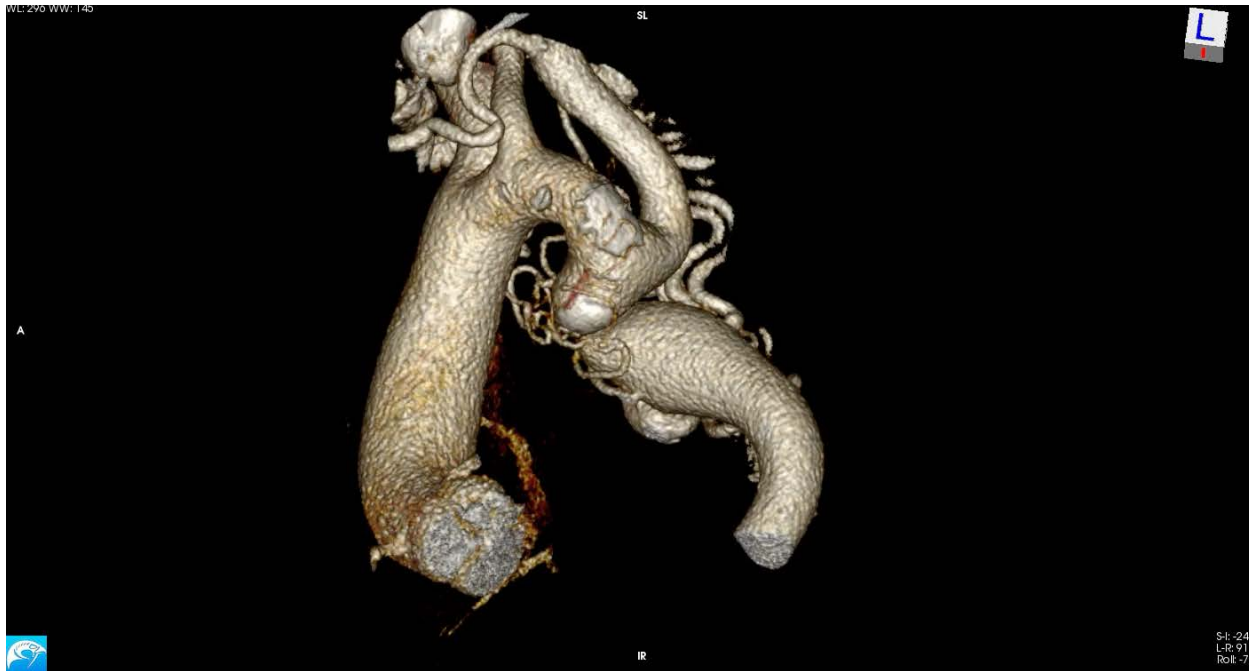In planning for TAVI a CTA was done....



Case



Case



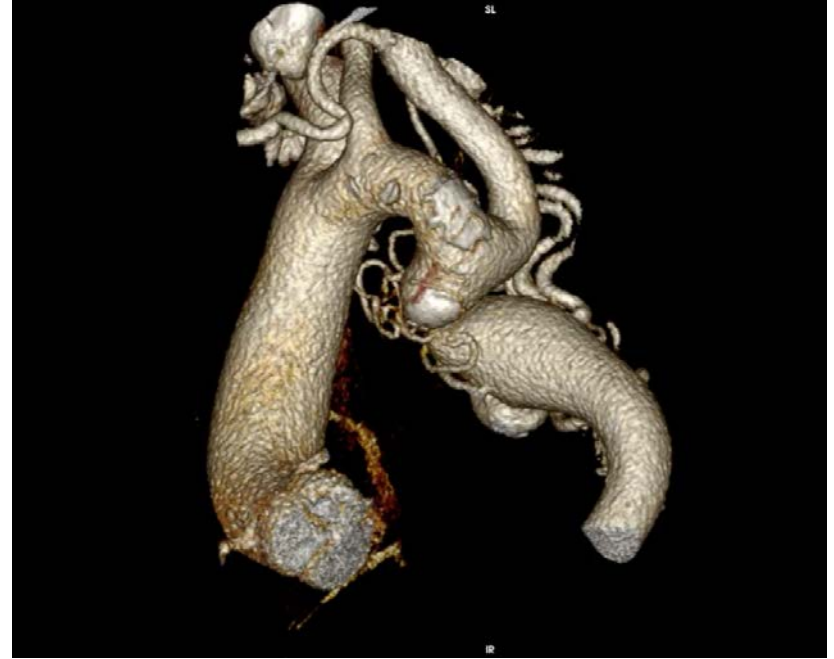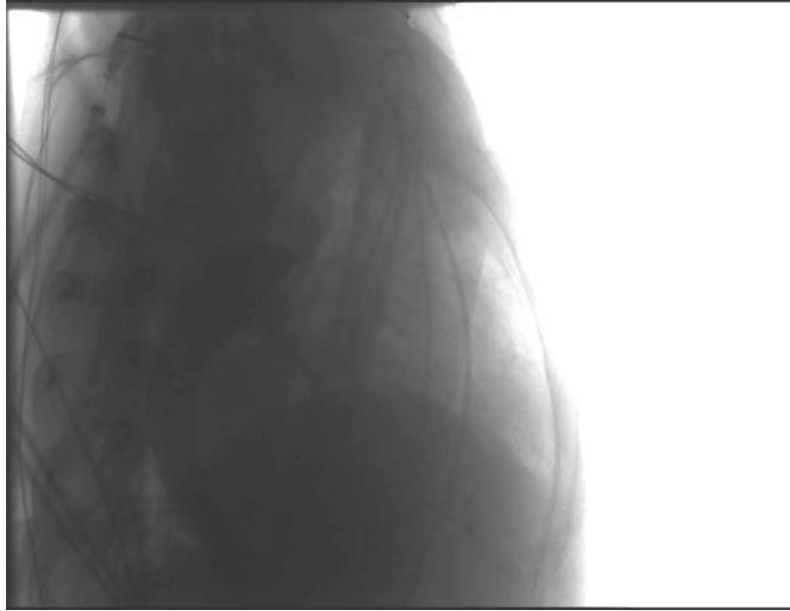
Case

MDT discussion:

1st step: CoA stenting

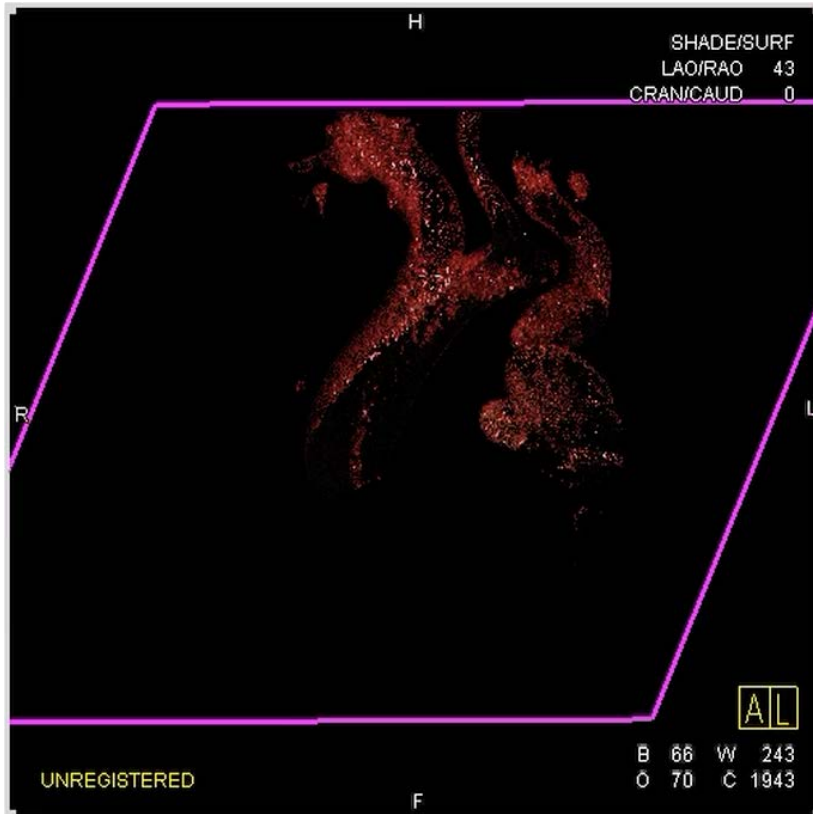
2nd step: TAVI 2-3 months later





Merge CT to 3D cath system





3DRA/CT:

subatretic CoA , normal arch branching,
massive collaterals .

Hypoplastic transvers Arch,

Desc pre-stenosis **26 mm**,

post-stenosis **29 mm**.

Distal of CoA collateral with aneurysm.



intervention

- implantation CPcovered stent 45mm lengte op BiB18x40 mm.
- 1-2 atm easy opening of CoA segment
- flaring of stent proximal and distal with CBV Balt 30x40 mm
- control angio: no dissection / paravasation/ aneurysm

conclusion

- Satisfying direct result of stenting subatretic native coarctation.

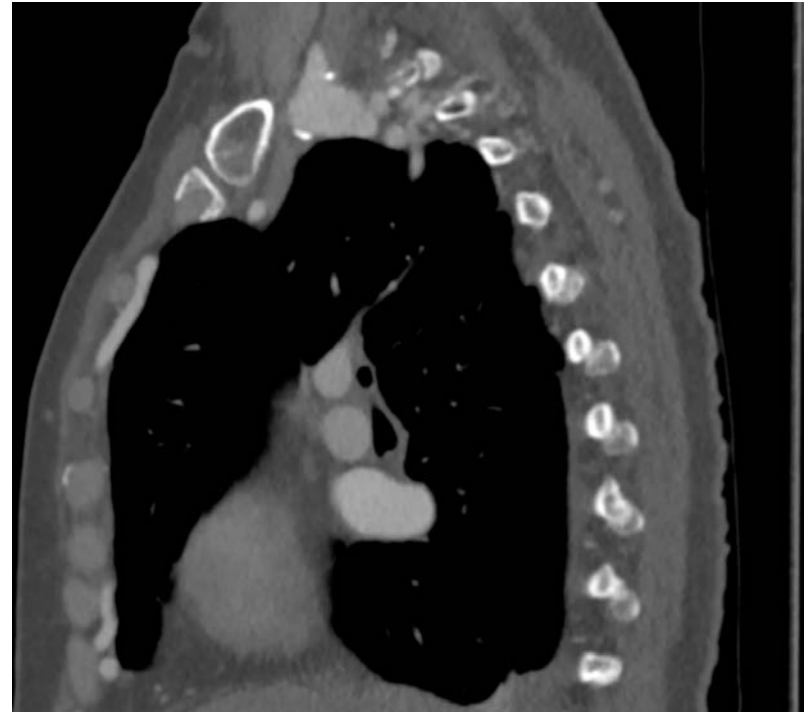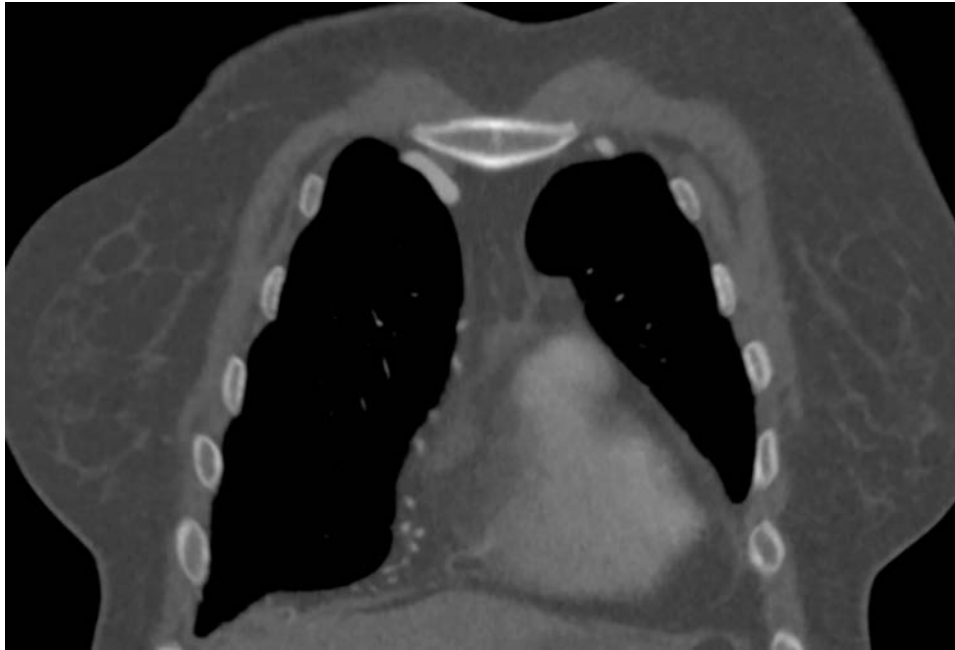Intention:

TAVI 2-3 months

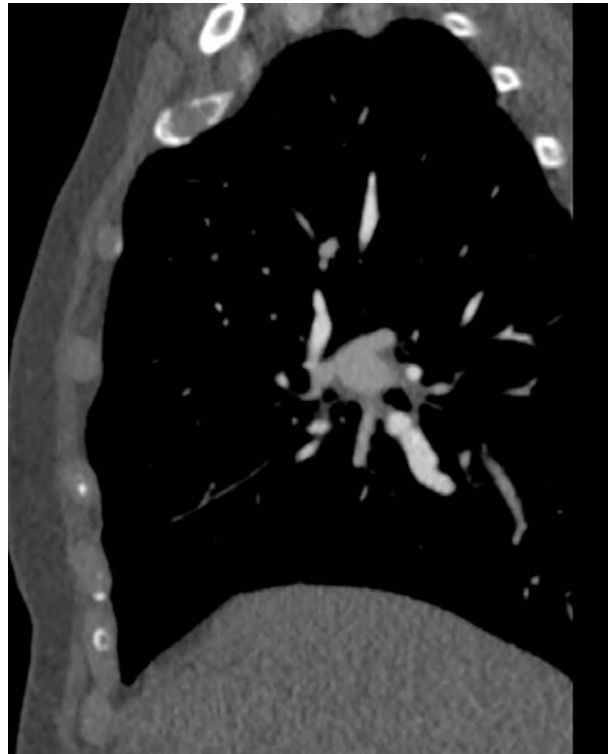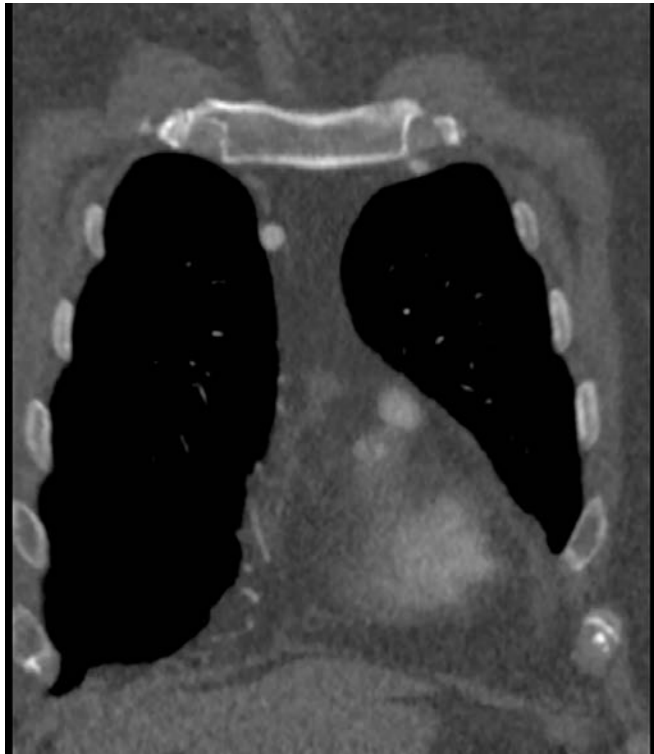Redilation CoA stent after that if needed



CTA 1 day after Cath



CTA 1 week after Cath



What would you do ?

- 1) Surgical
- 2) Interventional
- 3) watchful waiting





Children's Hospital

Case Continued this is what we did

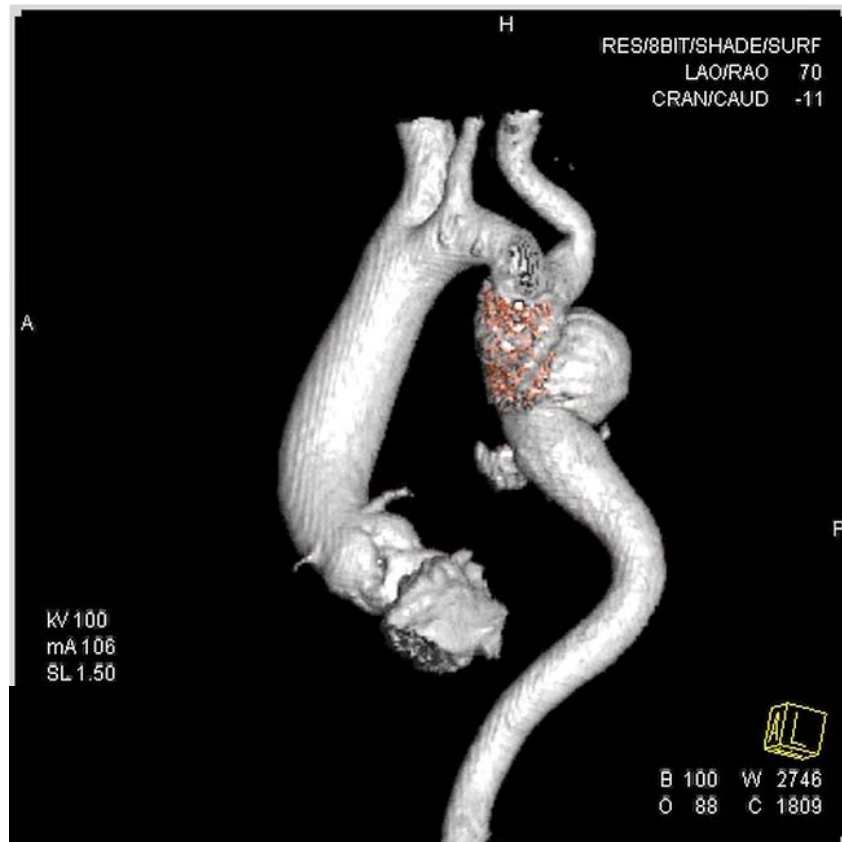
Mirella Molenschot

Pediatric (interventional) Cardiologist

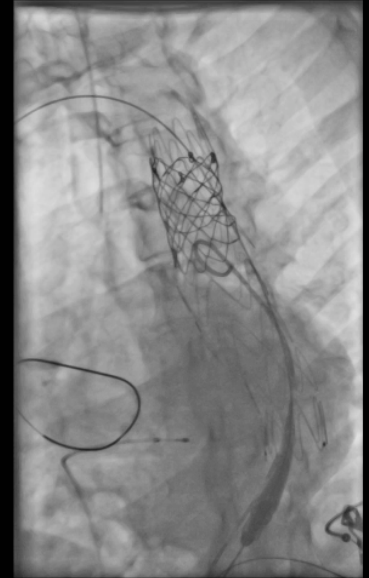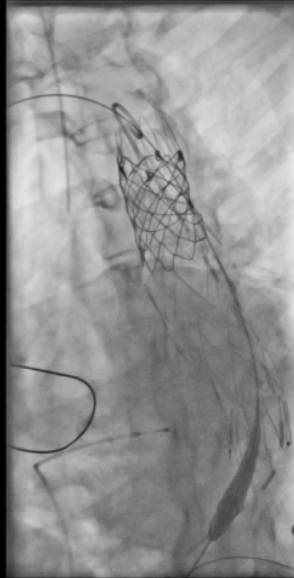
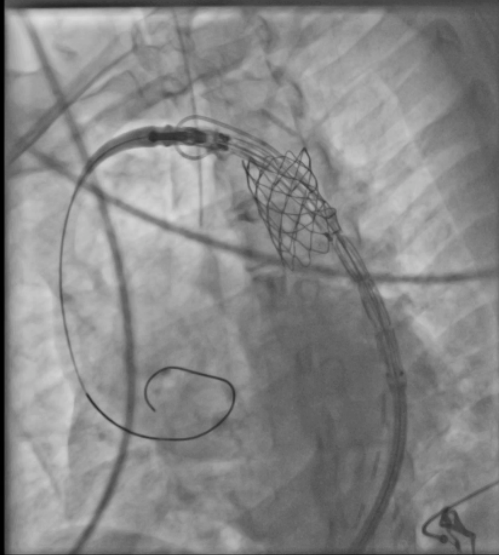


University Medical Center Utrecht

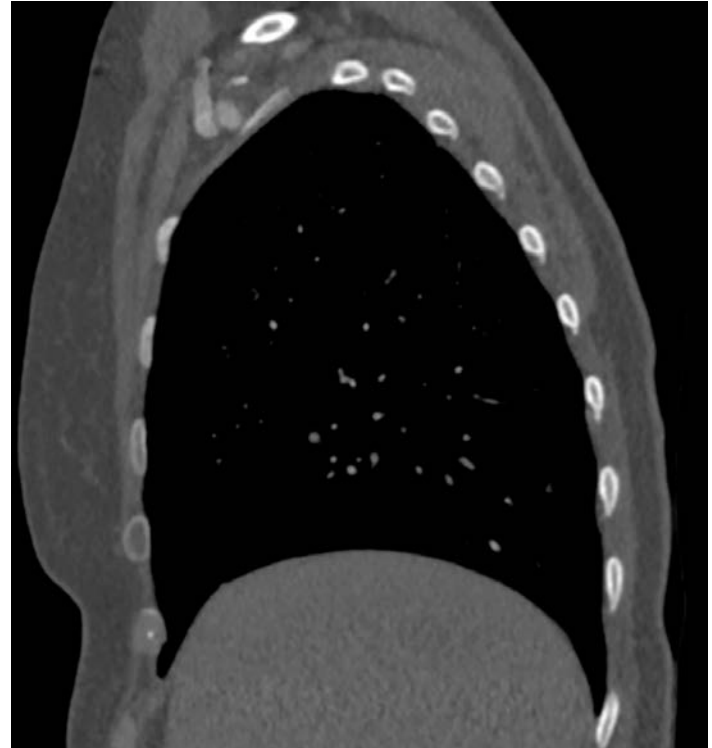
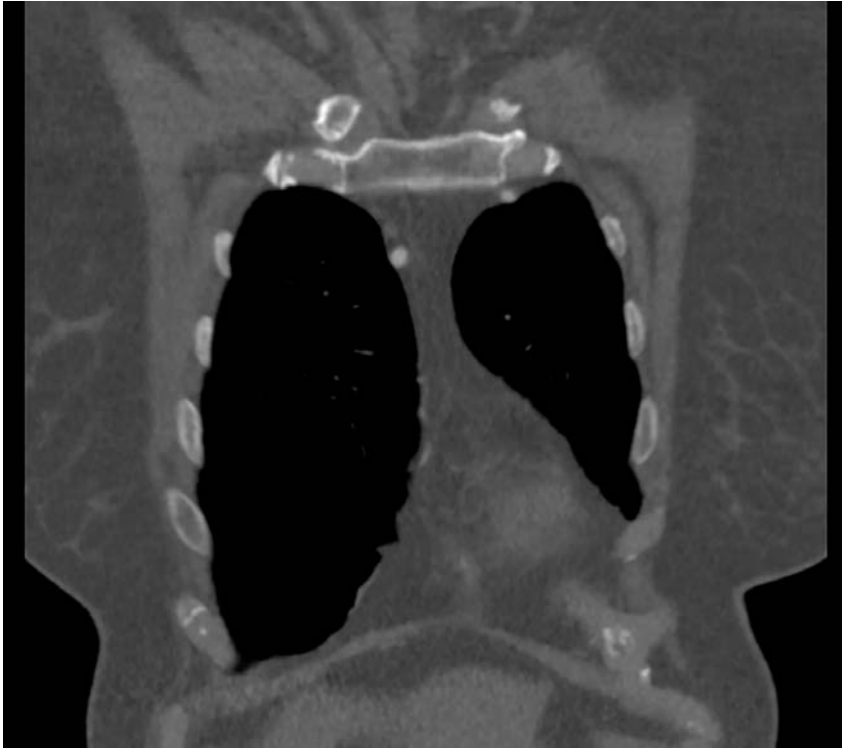
Re- Cath 1 month after 1st Cath



Re- Cath 1 month after 1st Cath



Follow up: CTA 2 months after TEVAR



Thank you for your participation !

