



I.R.C.C.S.
**POLICLINICO
SAN DONATO**

How to treat hypertension after CoA repair

“Stay out of stenting”

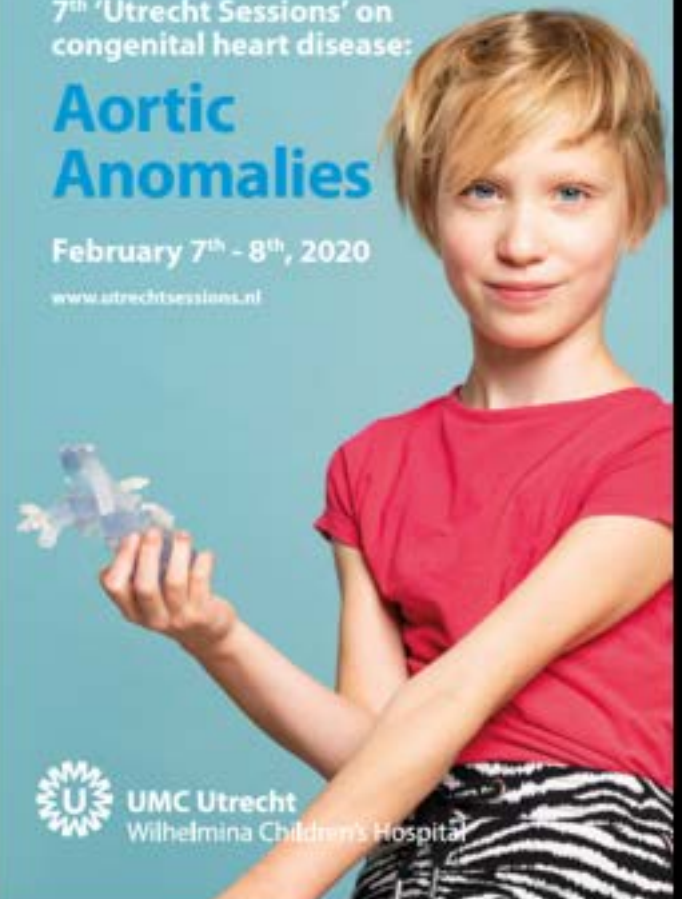*Mario Carminati
Pediatric and Adult Congenital Cardiology
IRCCS Policlinico San Donato*

7th 'Utrecht Sessions' on
congenital heart disease:

Aortic Anomalies

February 7th - 8th, 2020

www.utrechtsessions.nl



UMC Utrecht
Wilhelmina Children's Hospital

How to treat hypertension after CoA repair



*Mario! I decided to put you in a debate....
on treatment of recoarctation....
You will be against stenting!*



*Gregor! What the hell!
You know I am a fan
of stenting aortic arch!...*



Who will be my antagonist?

Darren Berman



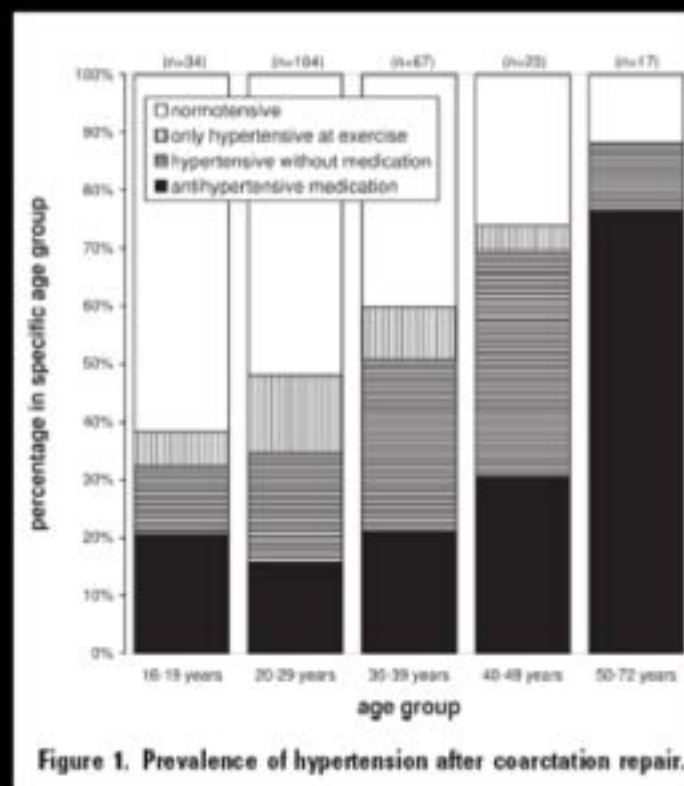
Wow! it is going to be tough!
I will try to do my best....



- ✓ Coarctation of the aorta is the fifth most common congenital heart defect, accounting for 6–8% of live births with congenital heart disease.
- ✓ Early-to-mid-term outcomes of patients with aortic coarctation are excellent, with early mortality rates as low as 2%.
- ✓ Approximately 30% of coarctation patients will be hypertensive by adolescence despite early surgery and more recent reports observe that about 60% of adults after correction of aortic coarctation in childhood are hypertensive

Most studies report resting blood pressure, but it is well established that a significant number of coarctation repair patients with normal resting blood pressure have an exaggerated blood pressure response to exercise which precedes the onset of overt hypertension

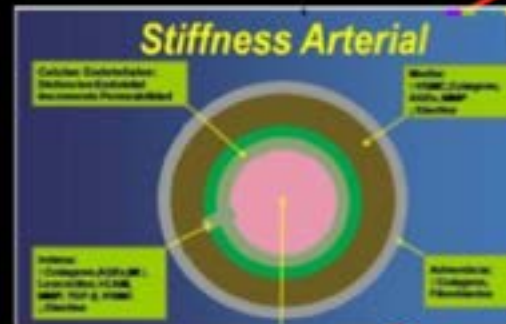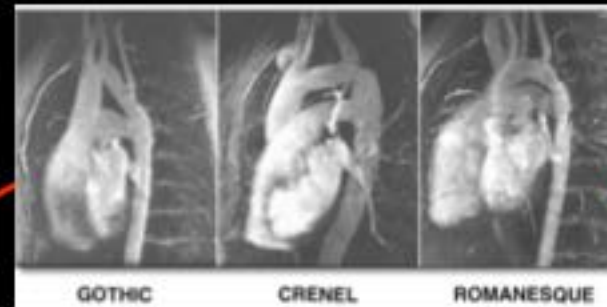
Criteria for hypertensive exercise response: peak systolic blood pressure higher than 220 mmHg in men and higher than 190 mmHg in women, peak diastolic blood pressure higher than 90 mmHg, or an increase in diastolic blood pressure greater than 10 mmHg.



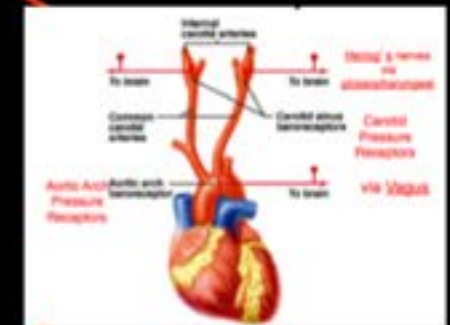
Hager et al. J Thorac Cardiovasc Surg. 2007

Relationship between aortic arch shape and blood pressure response after coarctation repair

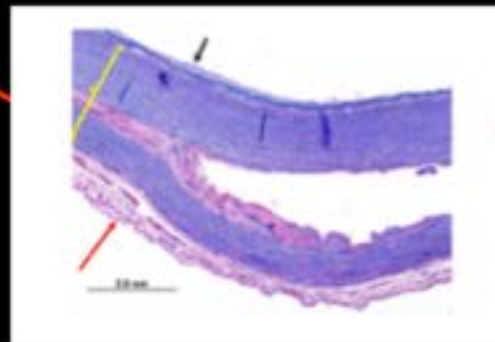
Arch Mal Coeur Vaiss. 2005 Jul-Aug



The mechanisms underlying arterial hypertension in corrected coarctation patients are not fully understood.



Vreind et al. Amsterdam,
Eur J Appl Physiol 2005



Vascular reactivity – baroreceptor reflex
Radke et al Germany, Heart 2014

Intrinsic abnormalities of the aortic wall
Mascherbauer et al Amsterdam, Heart 2014

European Heart Journal (2006) 27, 1603–1609




Clinical research

Late systemic hypertension and aortic arch geometry after successful repair of coarctation of the aorta

Phalla Ou^{1,2}, Damien Bonnet^{2,3,4}, Louis Auriaud², Elina Pedroni², Fanny Balleux², Daniel Sidi², Elie Mousseaux^{1,2}

¹ Cardologie Pédiatrique, Department of Pediatrics, Hôpital Necker-Enfants Malades, AP-HP, 161, rue de Serres, 75010 Paris, France

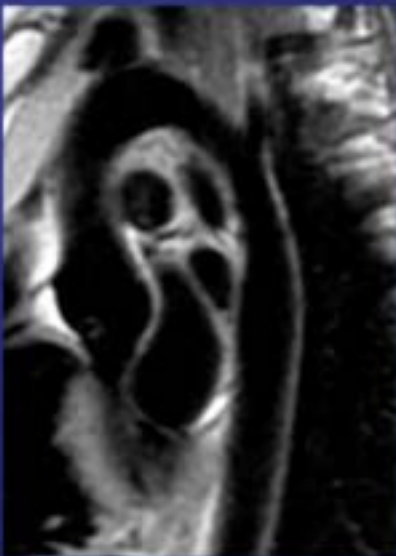
² INSERM U2016, Faculté de Médecine Necker-Enfants Malades, Paris, France

³ INSERM U2016, Faculté de Médecine Pitié-Salpêtrière, Paris, France

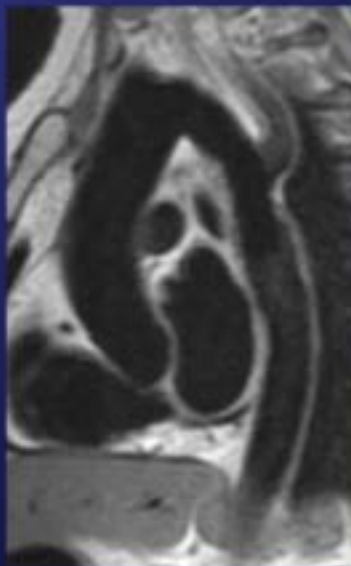
⁴ Service de Radiologie, Hôpital Européen Georges Pompidou, AP-HP, Paris, France

Received 27 January 2006, revised 2 July 2006, accepted 11 July 2006
Available online 14 September 2006

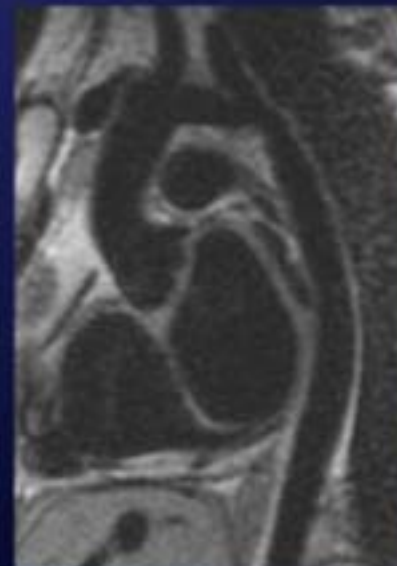
Aortic arch geometry



Romanesque



Gothic



Crenel

Coarctation Long-term Assessment (COALA): Significance of **arterial hypertension** in a cohort of 404 patients up to 27 years after surgical repair of isolated coarctation of the aorta, even in the absence of restenosis and prosthetic material

Alfred Hager, MD,^a Simone Kanz, MD,^a Harald Kaemmerer, MD, VMD, FESC,^a Christian Schreiber, MD,^b and John Hess, MD, FESC^a

Hager et al. *J Thorac Cardiovasc Surg.*2007; 134: 738-745

55% pts without re-stenosis were hypertensive

TABLE E1. Prevalence of hypertension according to the residual brachial-ankle blood pressure difference in the long-term follow-up after surgical coarctation repair

	brachial-ankle blood pressure difference		
	<0 mm Hg	0-20 mm Hg	>20 mm Hg
No. of patients			
With antihypertensive drug treatment	24 (22%)	33 (24%)	10 (36%)
Hypertensive without drug treatment	22 (20%)	33 (24%)	8 (29%)
Hypertensive only at exercise	8 (7%)	15 (11%)	3 (11%)
Normotensive	56 (51%)	54 (40%)	7 (25%)
Total	110 (100%)	135 (100%)	28 (100%)

Hager et al. J Thorac Cardiovasc Surg.2007

How to treat hypertension after CoA repair



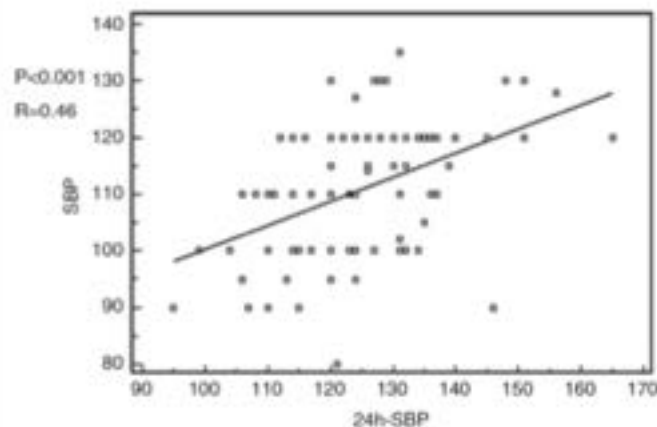
I.R.C.C.S.
POLICLINICO
SAN DONATO

Masked hypertension in young patients after successful aortic coarctation repair...

MH consists of an elevated daytime or awake ambulatory blood pressure (BP) in the presence of a normal BP on conventional measurement at the office.



MH occurred in 45% of AoC patients after optimal surgical or percutaneous treatment in neonatal or more advanced age.



MH is associated with abnormal left ventricle geometry and function

Di Salvo et al. Naples, J Hum Hypert 2011

How to treat hypertension after CoA repair



I.R.C.C.S.
POLICLINICO
SAN DONATO

Persistent hypertension (post Coarctation repair)
with “mild” recoarctation

Difficulty in controlling hypertension
with medical treatment

Is relieving “mild” residual obstruction effective
in relieving hypertension?

How to treat hypertension after CoA repair



I.R.C.C.S.
POLICLINICO
SAN DONATO

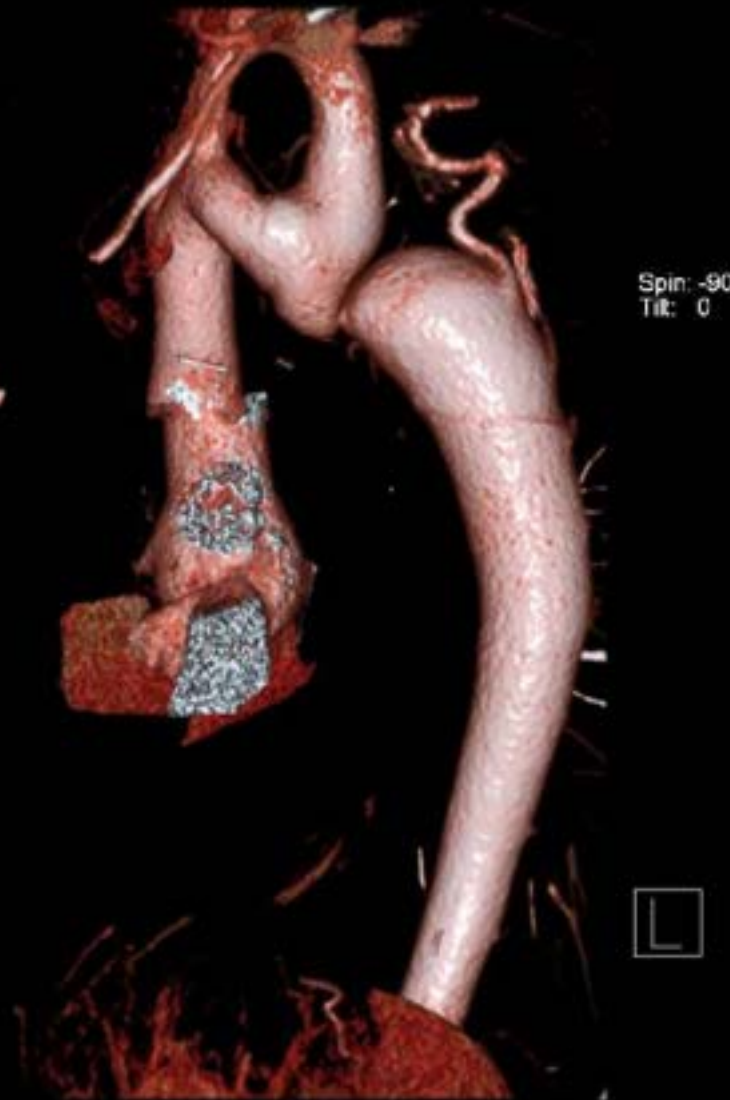Age: 18 yrs

Weight: 60 Kg; **Height** 170 cm

Since 12 yrs of life: systemic arterial hypertension

CT Scan: severe aortic coarctation+ tortuous aortic arch

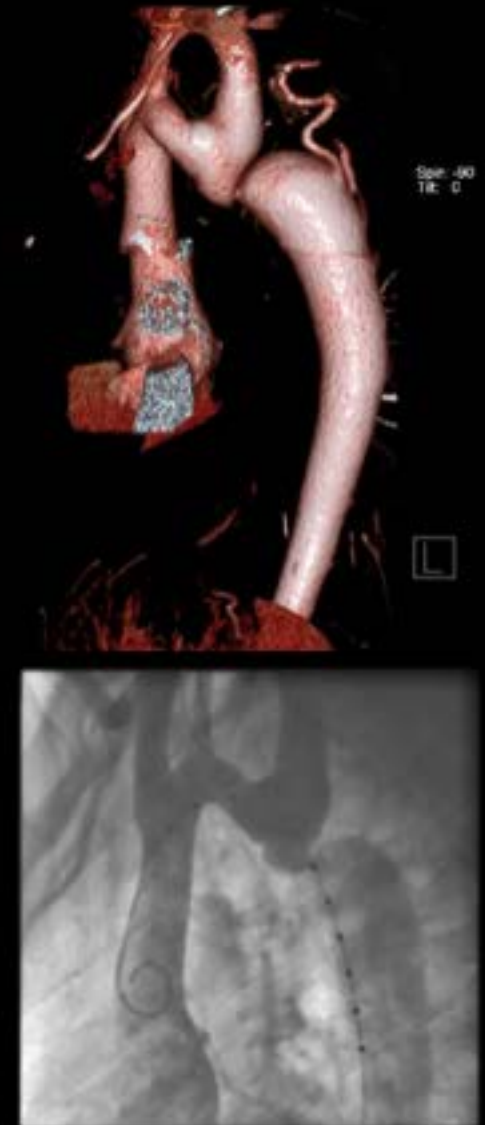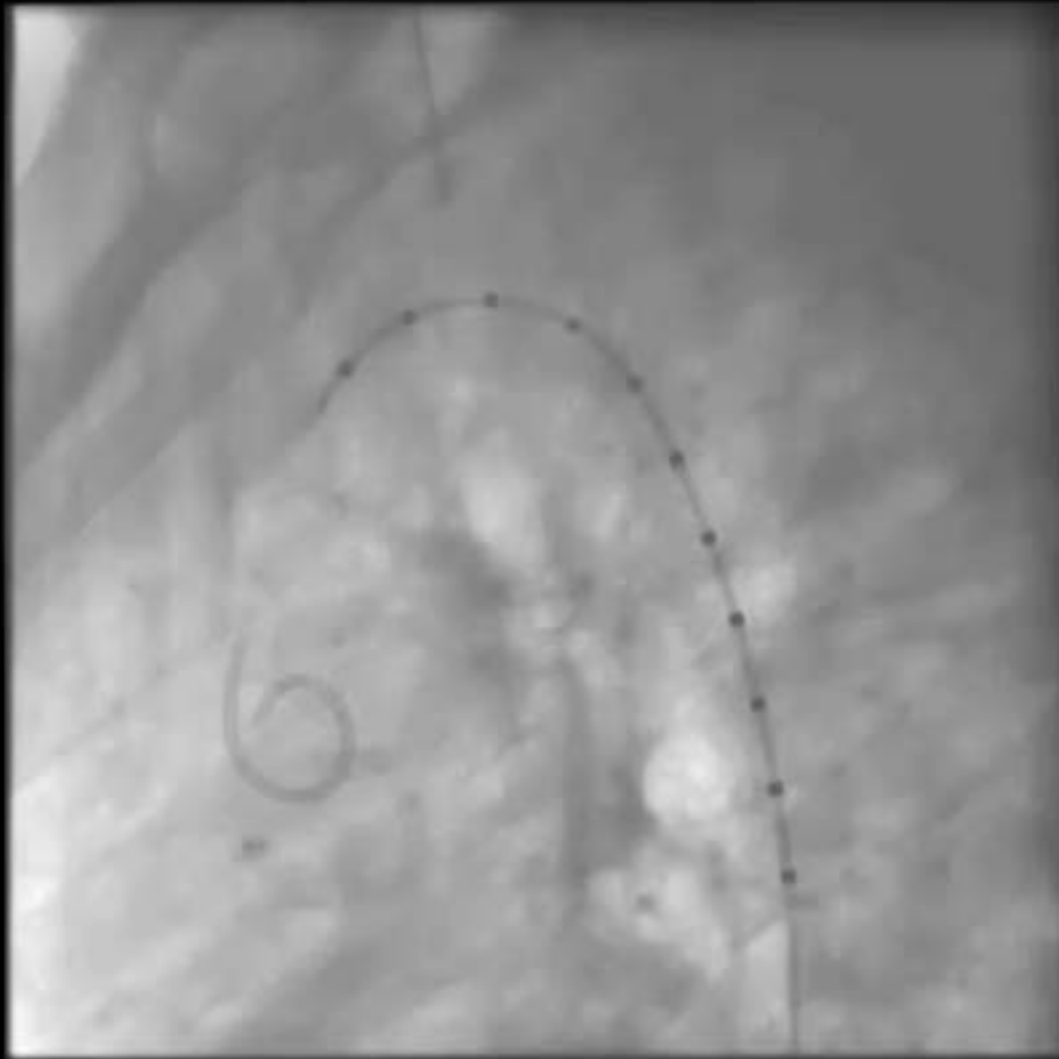
Hemodynamic assessment:
peak to peak gradient: 70 mmHg



How to treat hypertension after CoA repair



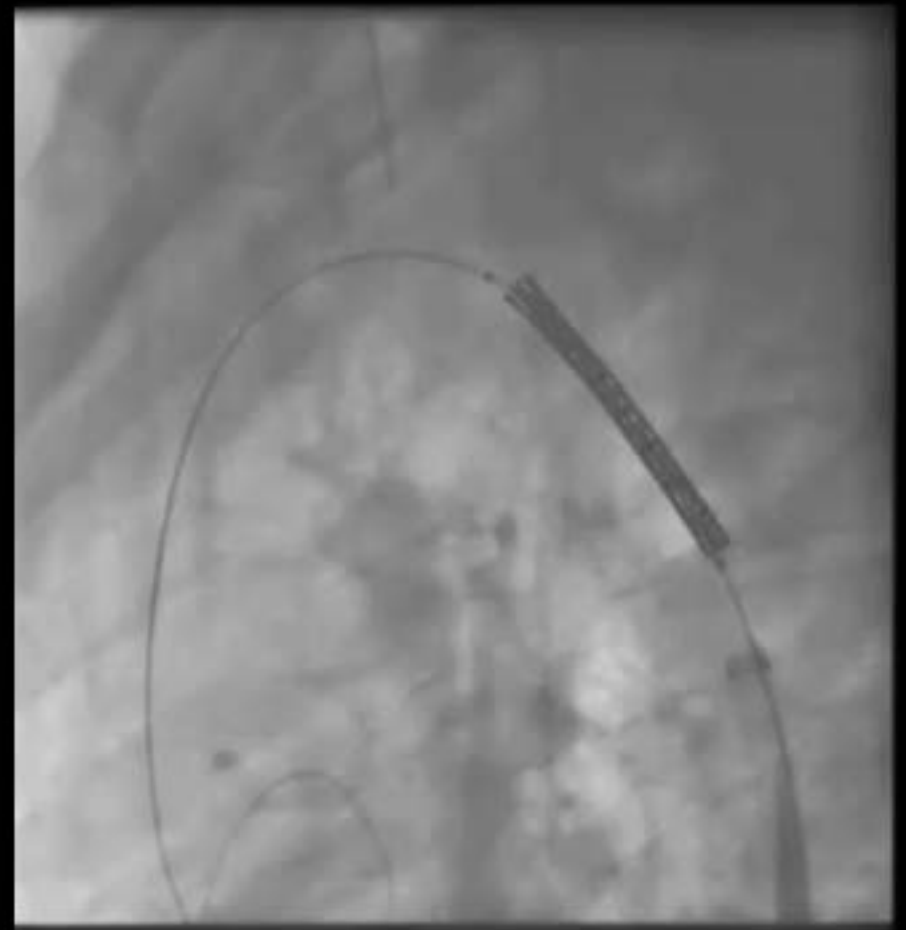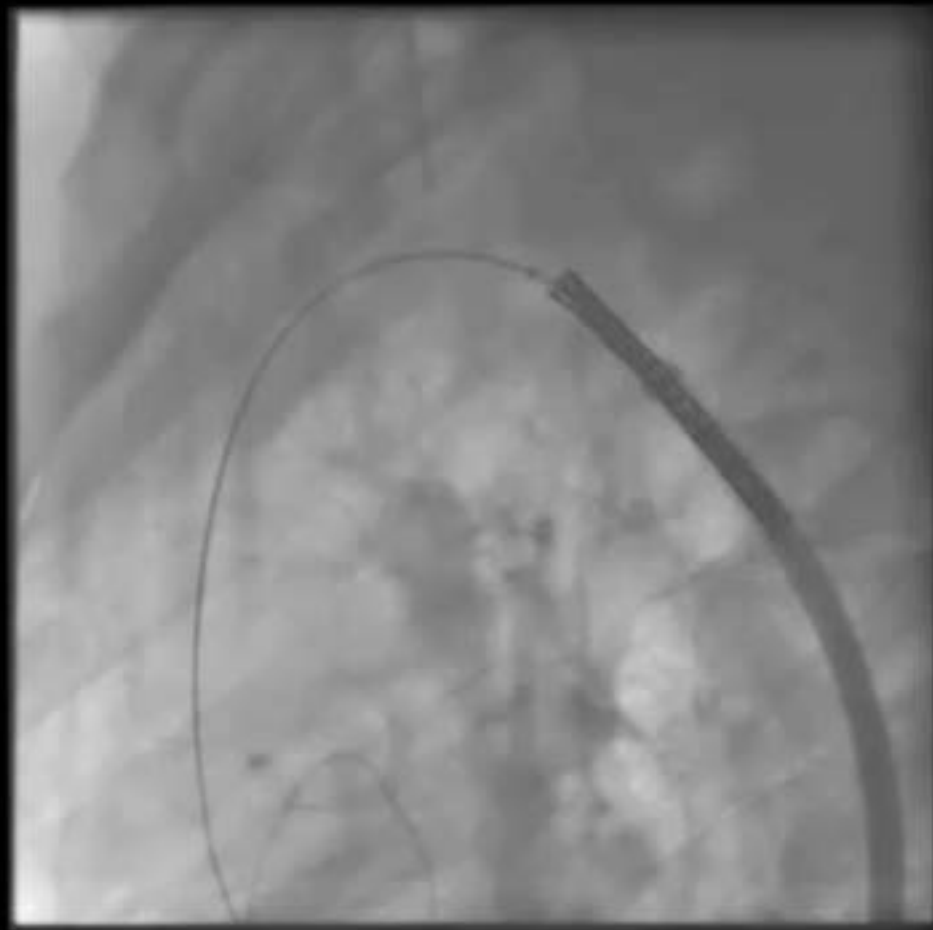
I.R.C.C.S.
POLICLINICO
SAN DONATO



How to treat hypertension after CoA repair

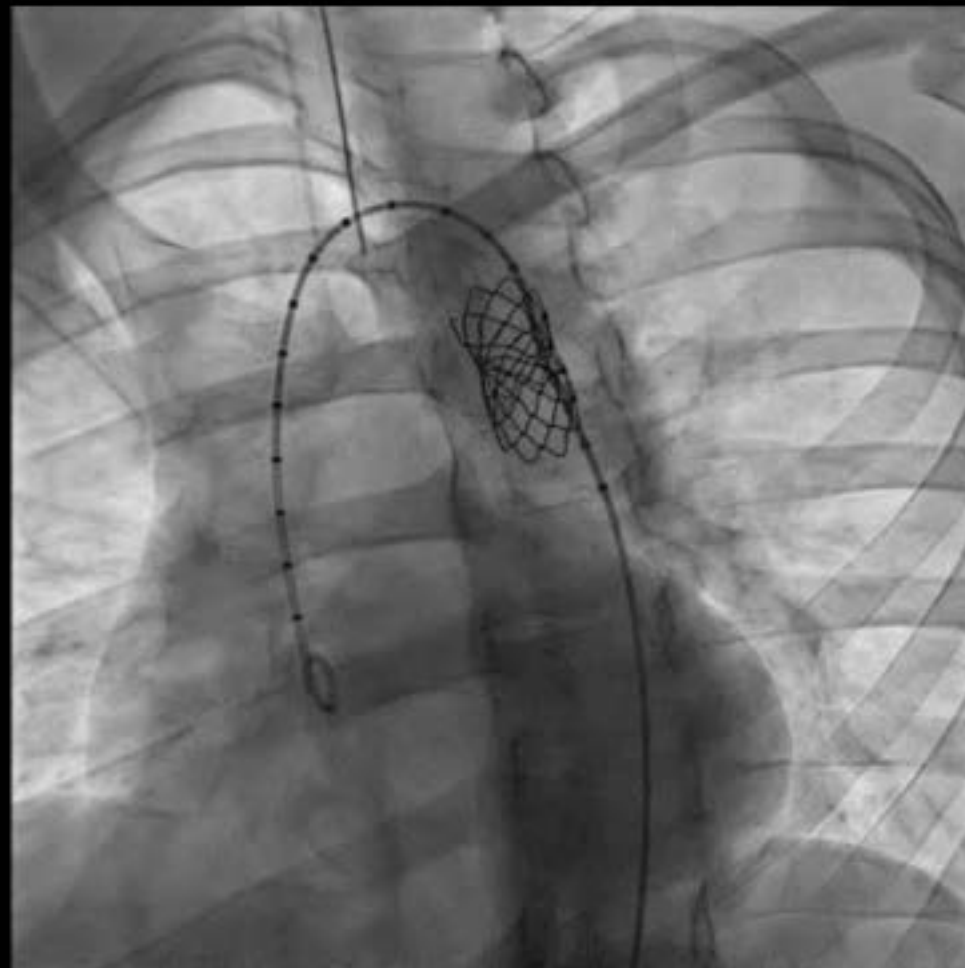
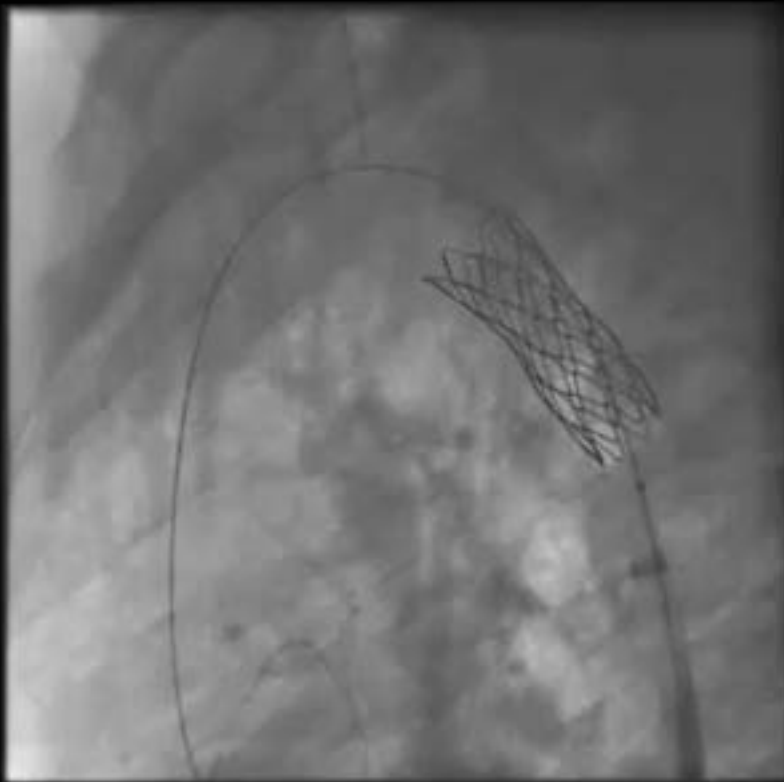


**I.R.C.C.S.
POLICLINICO
SAN DONATO**



CP Covered stent 45 mm on Cristal Balloon 18x50 mm

How to treat hypertension after CoA repair



Final result: no significant residual gradient (< 10 mmHg)

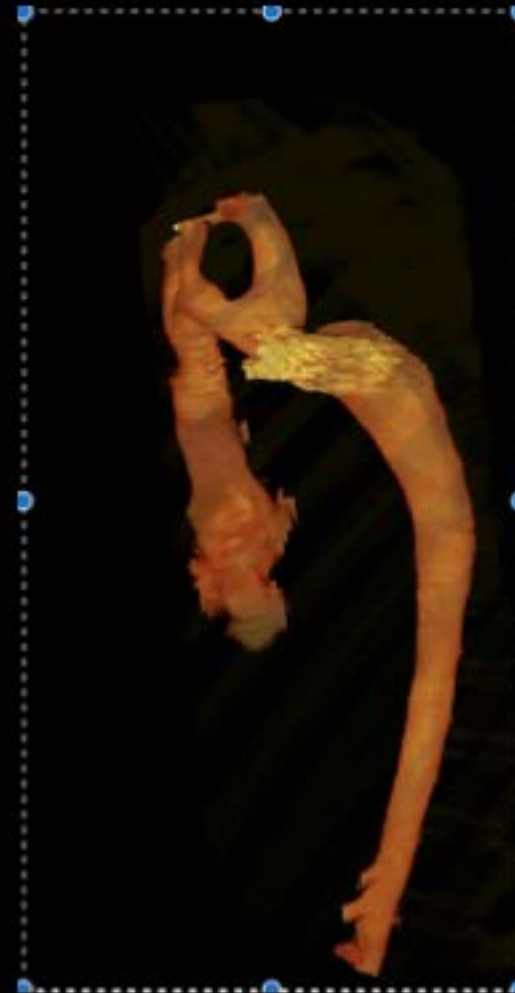
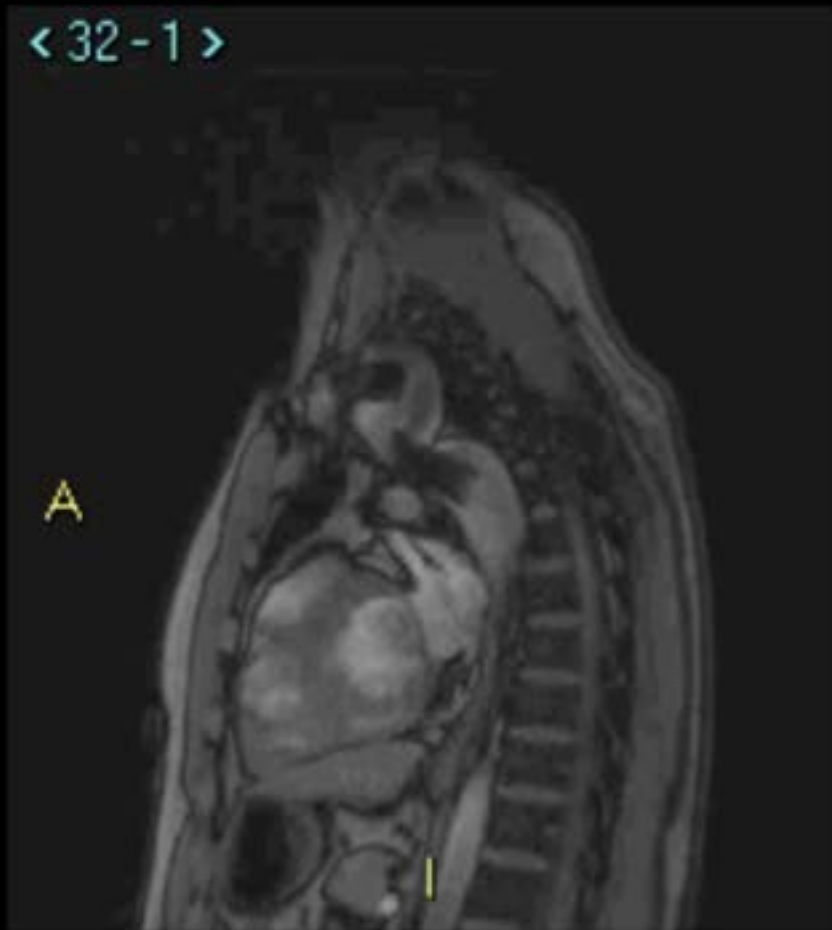How to treat hypertension after CoA repair



I.R.C.C.S.
POLICLINICO
SAN DONATO

Follow up: 4 yrs after stenting

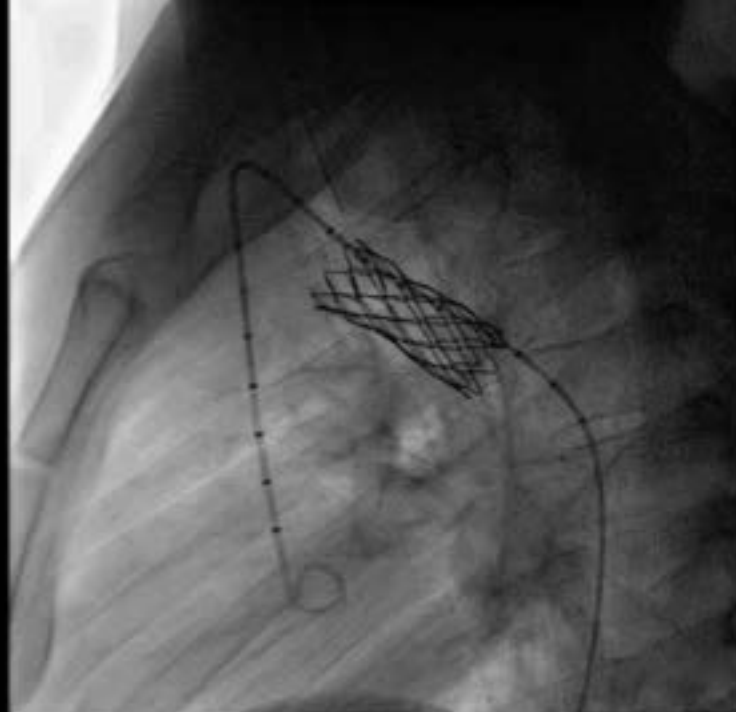
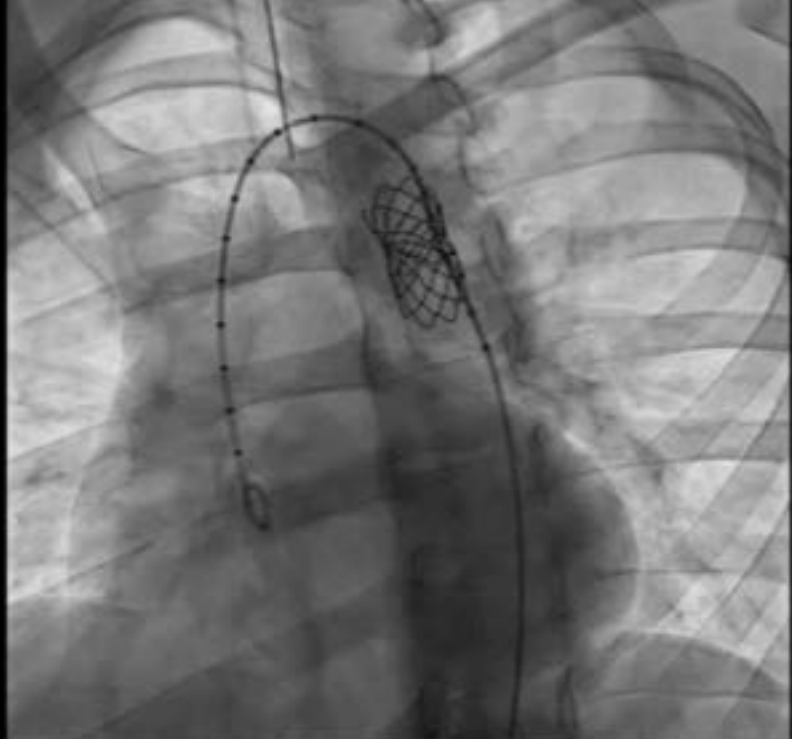Clinical condition: residual systemic hypertension



How to treat hypertension after CoA repair



I.R.C.C.S.
POLICLINICO
SAN DONATO



Hemodynamic assessment: Grad peak to peak Asc Ao/Proximal arch: 10 mmHg
Grad peak to peak Aortic Arch-Desc Ao: 5 mmHg
Grad peak to peak intrastent: <10 mmHg



*medical treatment should be the best choice
as opposed to any additional interventional procedure*

How to treat hypertension after CoA repair



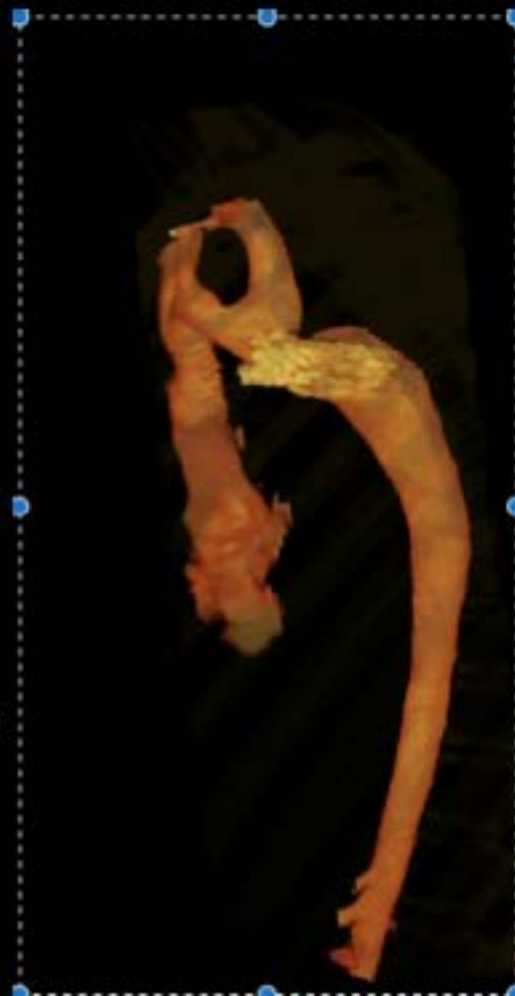
I.R.C.C.S.
POLICLINICO
SAN DONATO

Need to make a “balance” between:

Complex anatomy unfavorable for stenting

and

Uncertain effectiveness of risky stenting procedure



How to treat hypertension after CoA repair



I.R.C.C.S.
POLICLINICO
SAN DONATO

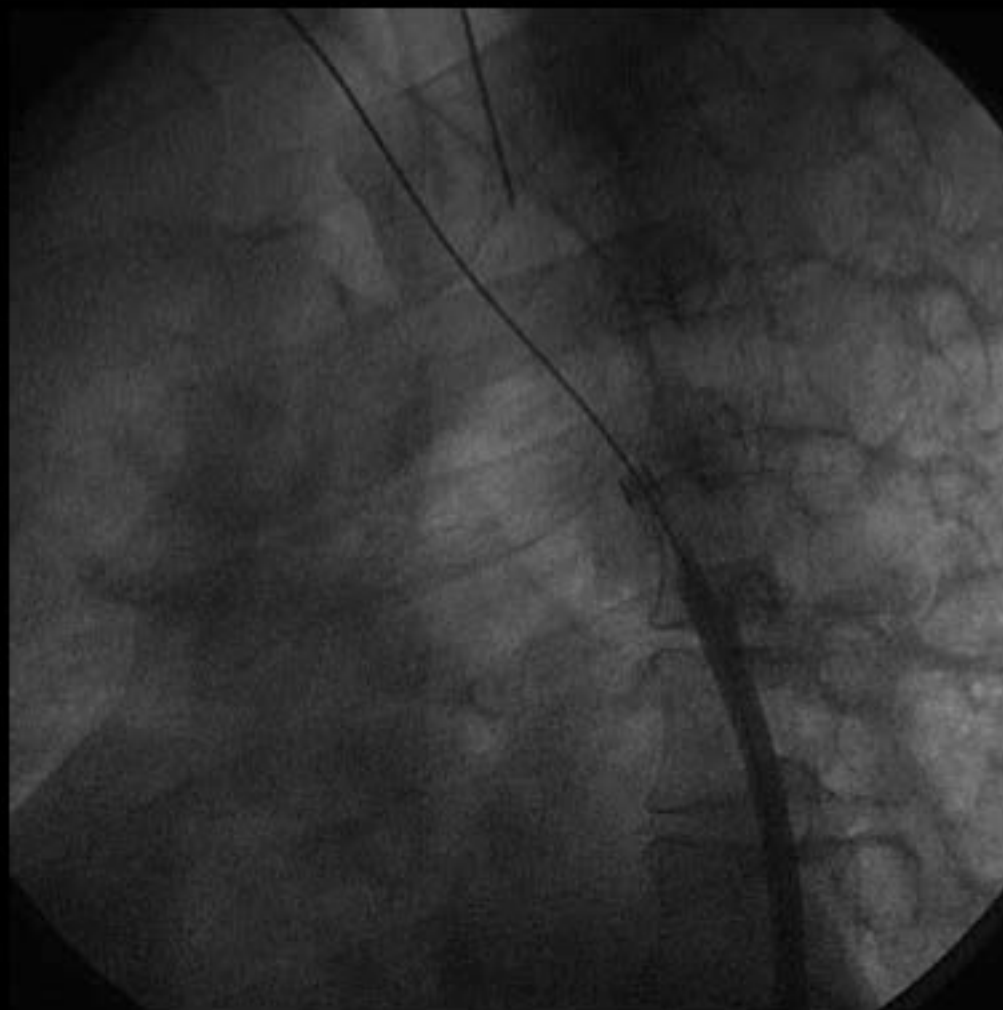
Diagnosis: Recoarctation

Age: 50 years

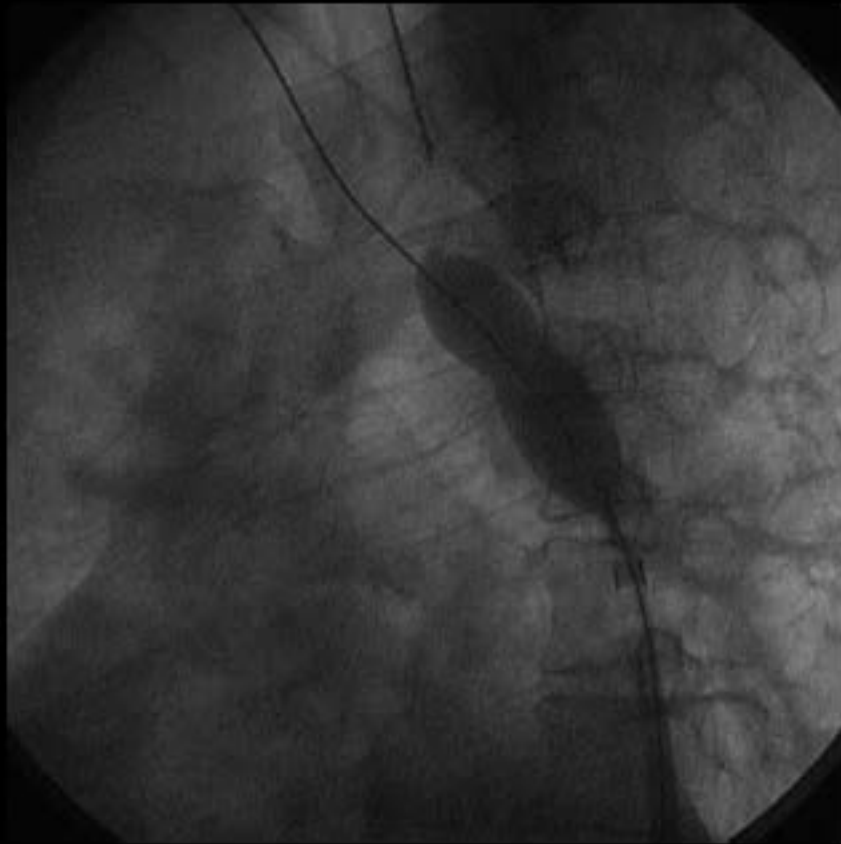
Previous surgery at 10 y.: end to end anastomosis

Clinical status: moderate hypertension (triple medications)

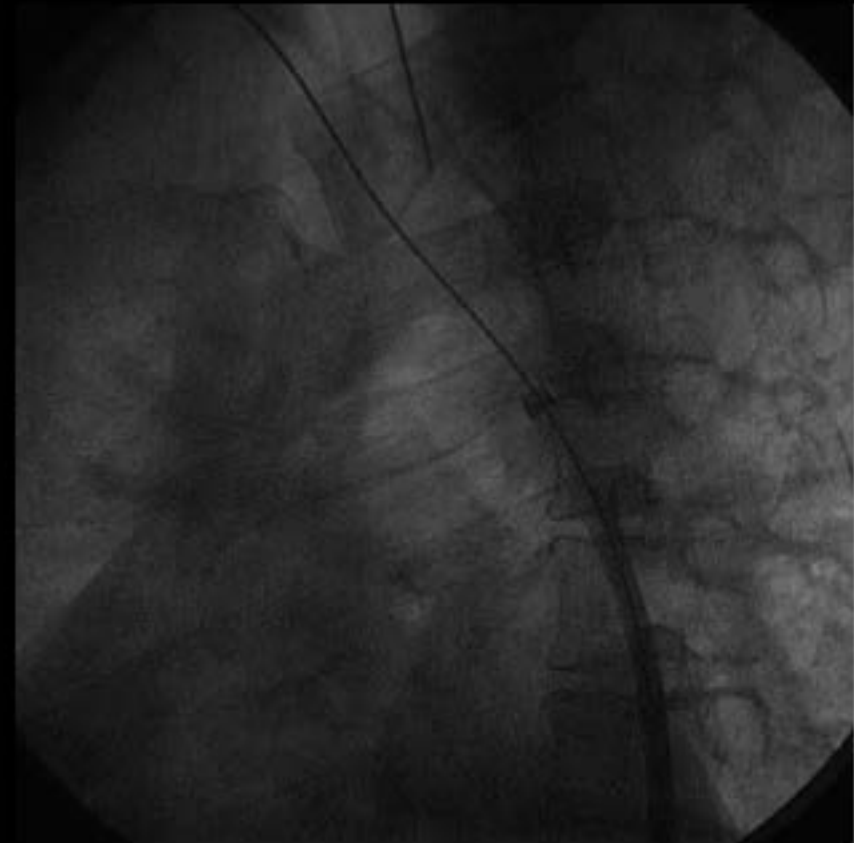Hemodynamic assessment:
peak to peak gradient: 30 mmHg



How to treat hypertension after CoA repair



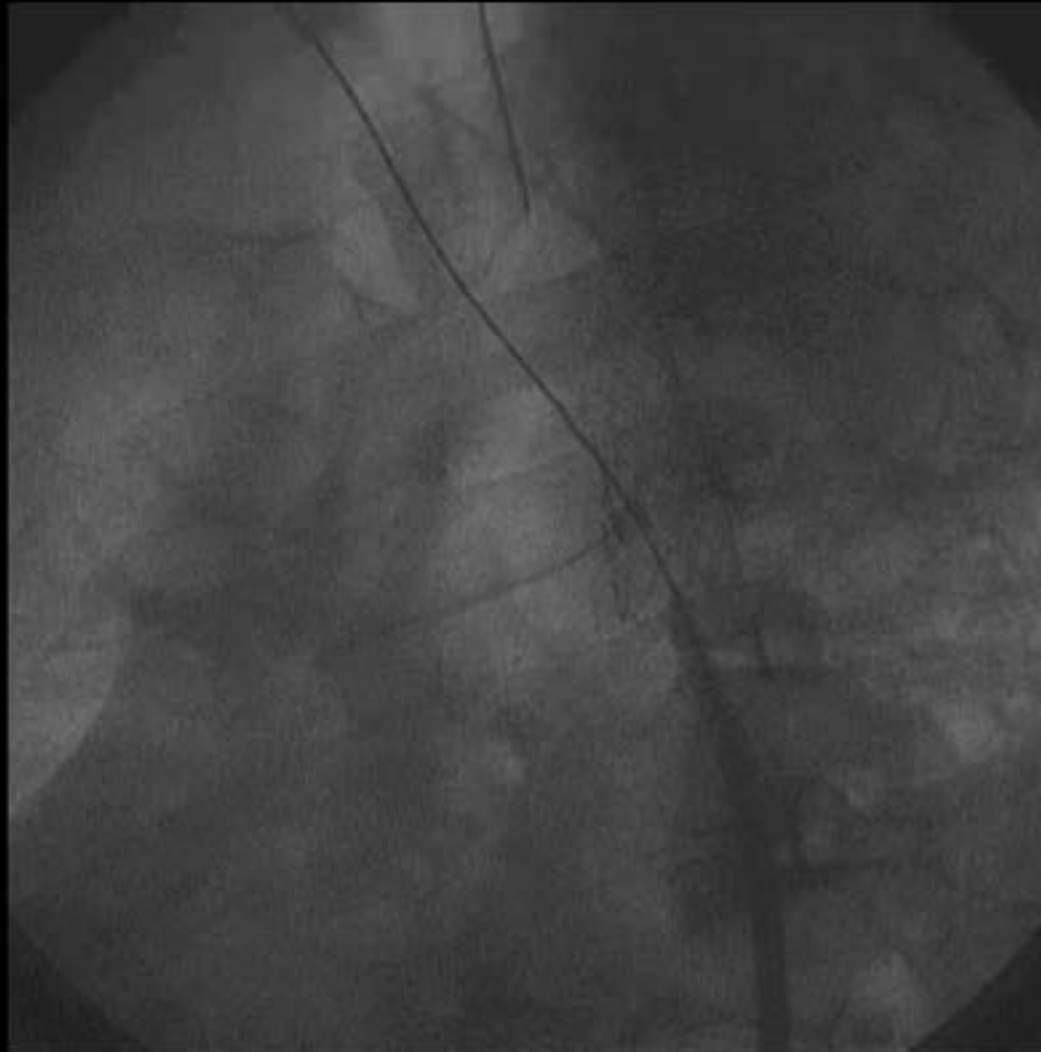
Balloon dilation



Angio post-balloon: unchanged

How to treat hypertension after CoA repair

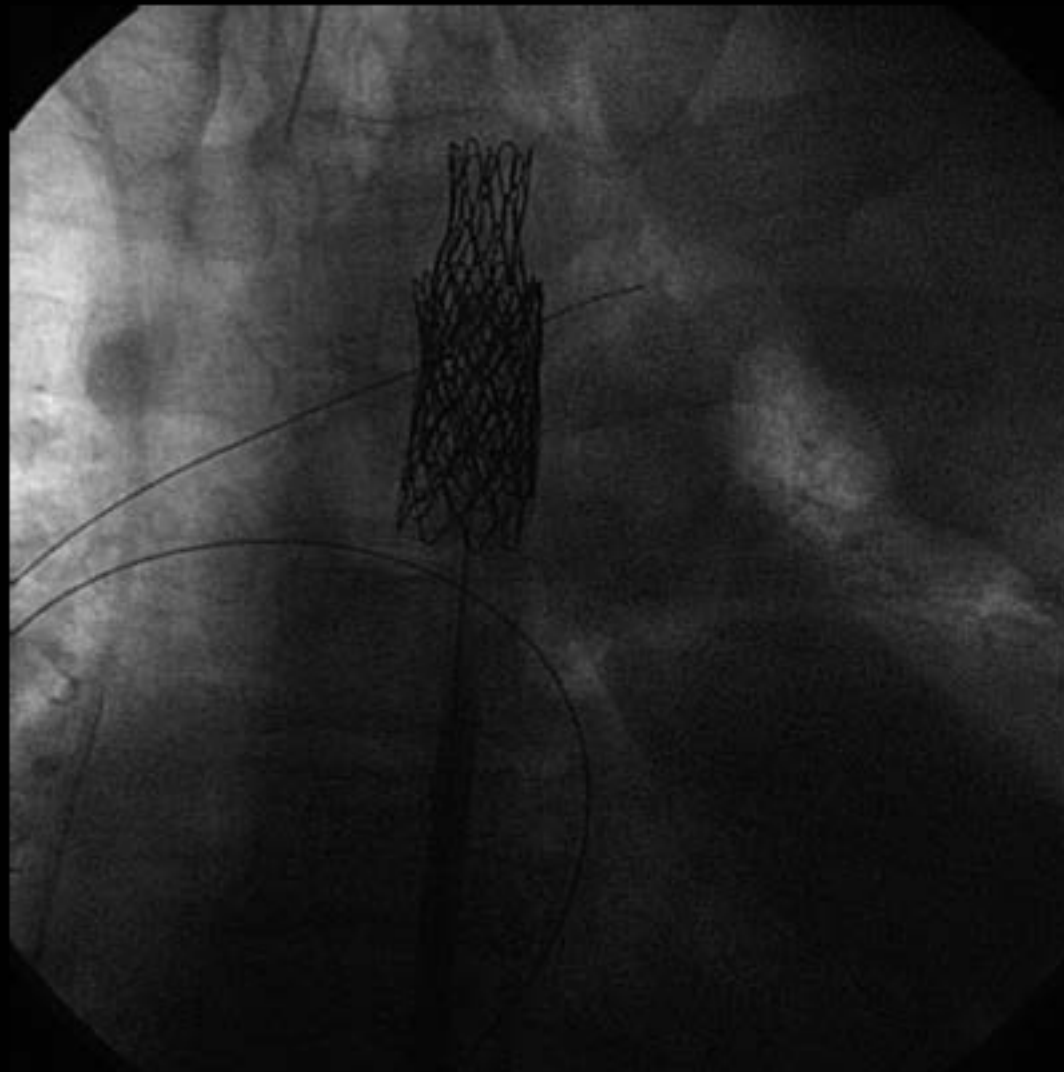
Bare metal stent implantation



How to treat hypertension after CoA repair



Covered stent implantation, surgery



How to treat hypertension after CoA repair

**How to treat hypertension after CoA repair:
without the evidence
of severe anatomic obstruction.....**

“Stay out of stenting”

How to treat hypertension after CoA repair



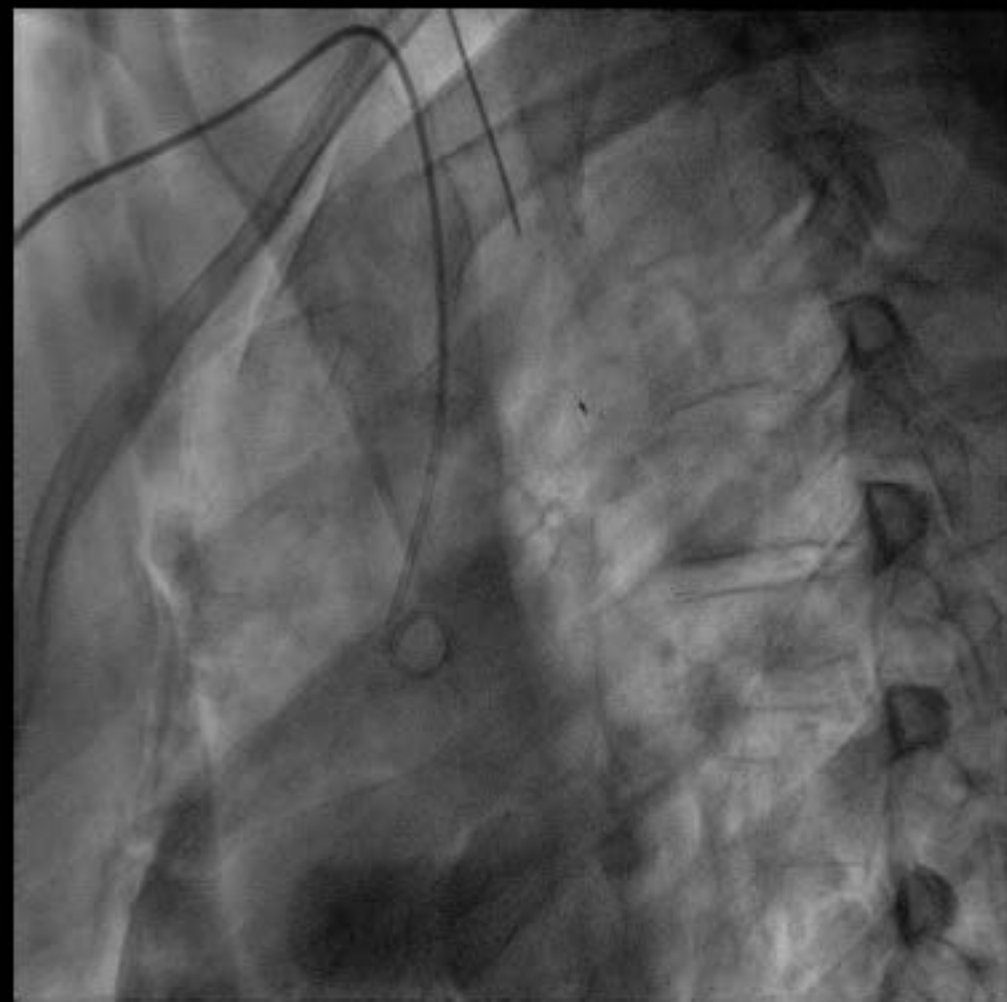
Diagnosis: Recoarctation

Age: 17years

Previous surgery at 3 days: subclavian flap, then balloon angioplasty at 3 years.

Clinical status: moderate hypertension. very intense sport activity

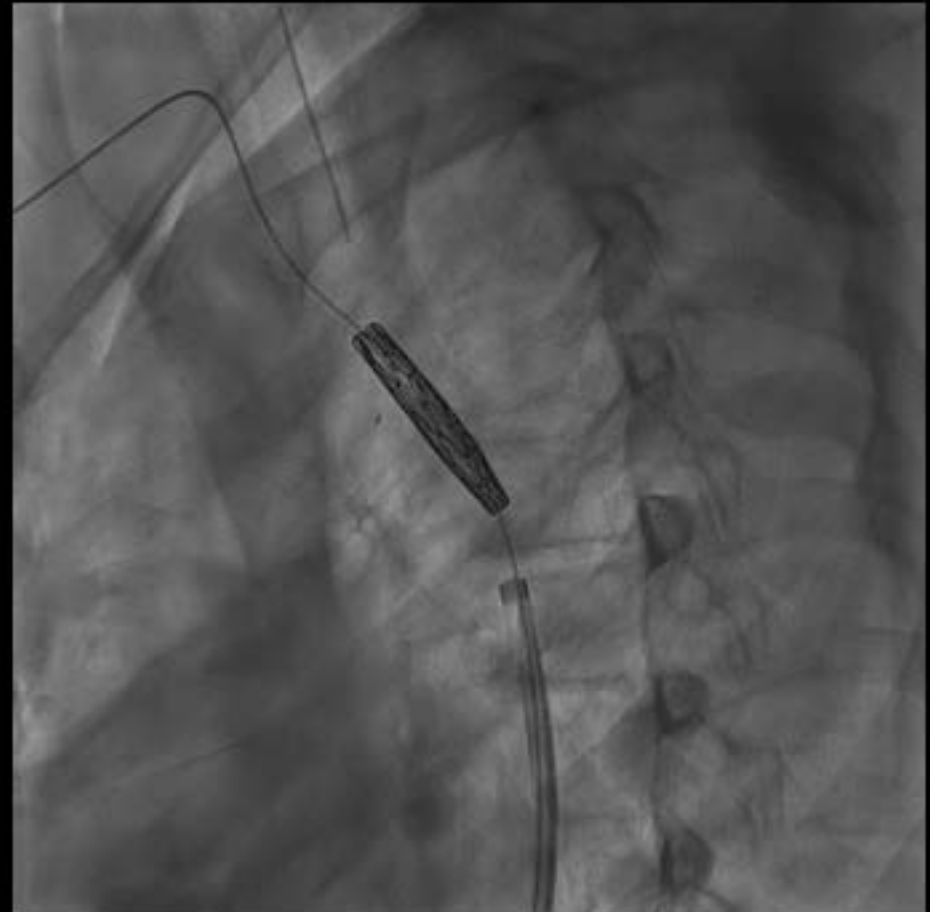
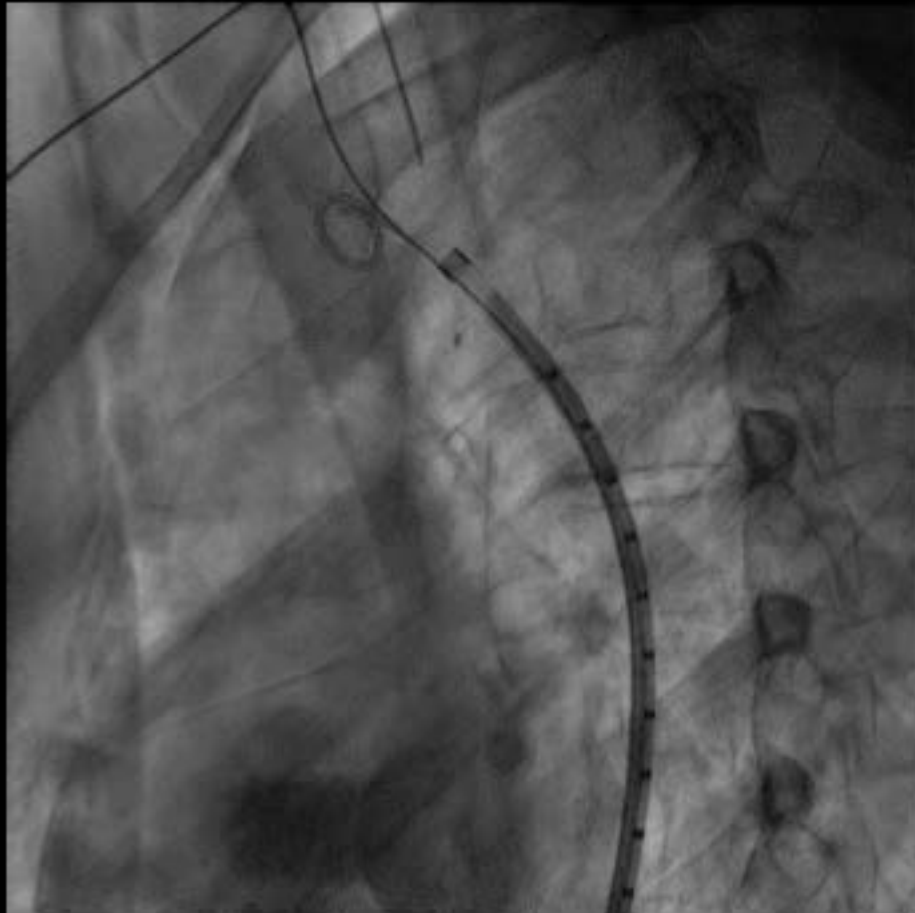Hemodynamic assessment:
peak to peak gradient: 35 mmHg +
aneurysm



How to treat hypertension after CoA repair



CP covered stent

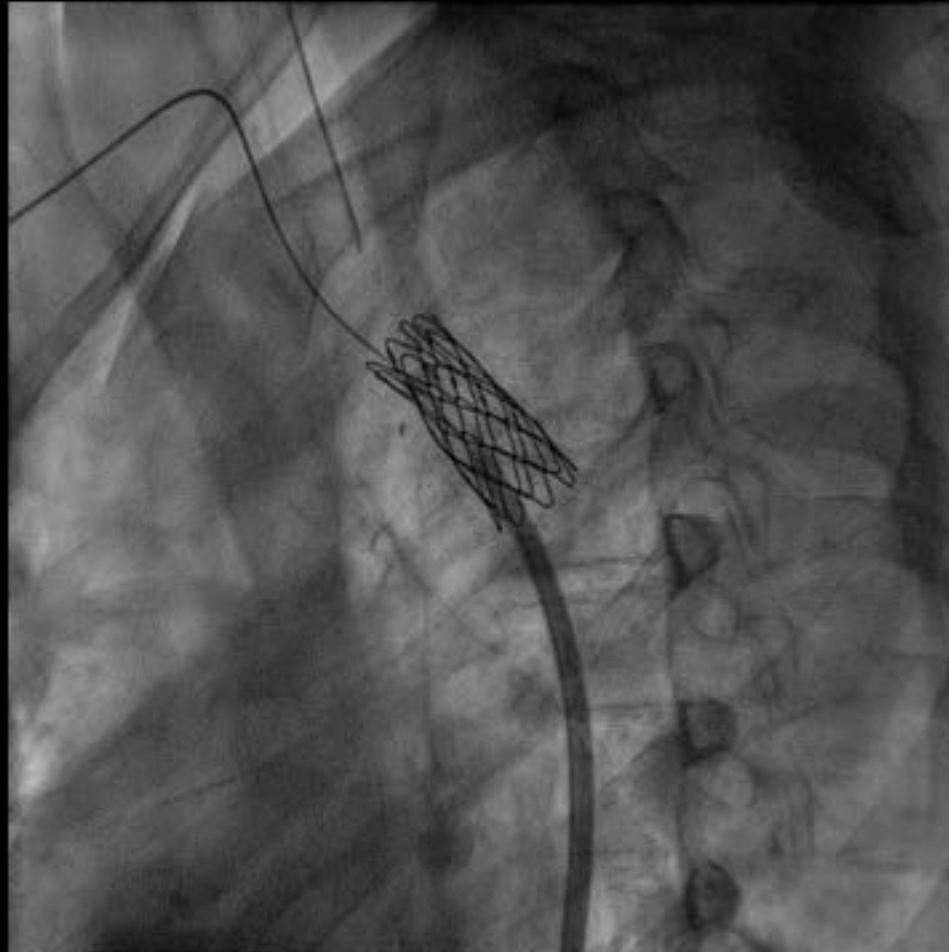


How to treat hypertension after CoA repair



**CP covered stent - no residual gradient
Aneurysm disappeared**

Aneurysm disappeared



How to treat hypertension after CoA repair



I.R.C.C.S.
POLICLINICO
SAN DONATO

How to treat hypertension after CoA repair:

“Stay out of stenting”

(in cases of isolated mild residual obstruction)

**...or... if you decide to implant a stent,
use covered stent as much as you can!**

How to treat hypertension after CoA repair



I.R.C.C.S.
POLICLINICO
SAN DONATO

Thank you!

Mario Carminati