The morphology of hypoplastic leaft heart

Annalisa Angelini , MD, FESC

Dept of Cardiac, Thoracic and Vascular Sciences and Public Health

University of Padua, Padua, Italy

Utrecht Sessions

The Center for Congenital Heart Defects

Invitation 8th 'Utrecht Sessions'
2nd - 4th February 2023
Hypoplastic Left Heart Syndrome from fetus to stage I

Word Cloud

- Digit one word link to Hypoplastic left heart syndrome

Layout of my presentation

- Terminology HLHS
- LV morphology
- Aortic valve morphology
- Left atrium and atrial septum morphology
- RV and tricuspid valve

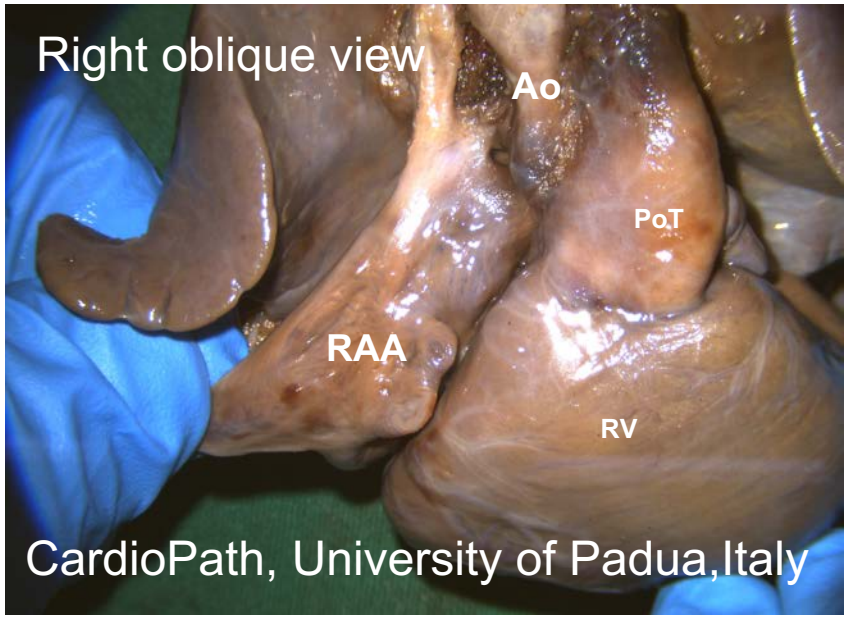

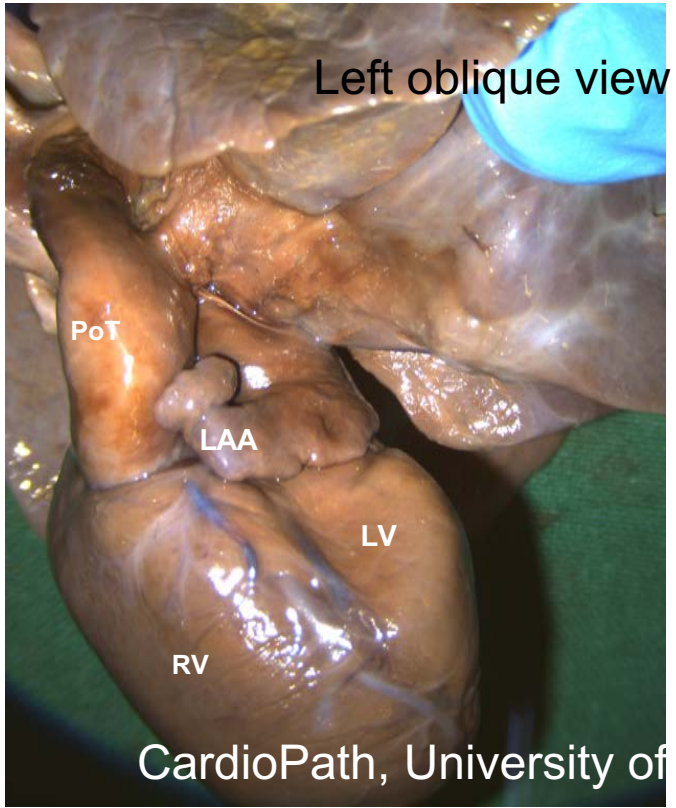

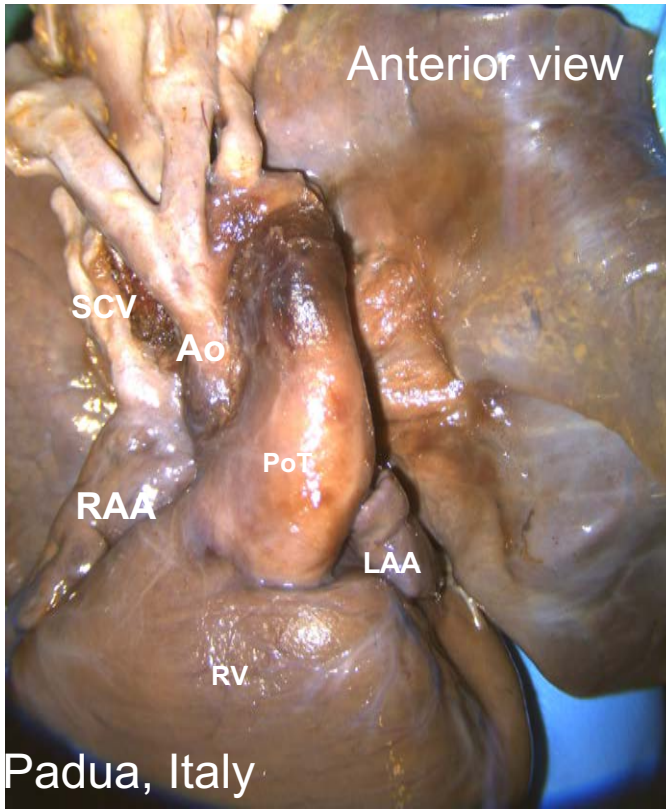

Hypoplastic leaft heart

European Journal of Cardio-Thoracic Surgery 58 (2020) 416–499
doi:10.1093/ejcts/ezaa188

GUIDELINES

Cite this article as: Alphonso N, Angelini A, Barron DJ, Bellsham-Revell H, Blom NA, Brown K *et al.* Guidelines for the management of neonates and infants with hypoplastic left heart syndrome: The European Association for Cardio-Thoracic Surgery (EACTS) and the Association for European Paediatric and Congenital Cardiology (AEPC) Hypoplastic Left Heart Syndrome Guidelines Task Force. Eur J Cardiothorac Surg 2020;58:416–99.

Guidelines for the management of neonates and infants with hypoplastic left heart syndrome: The European Association for Cardio-Thoracic Surgery (EACTS) and the Association for European Paediatric and Congenital Cardiology (AEPC) Hypoplastic Left Heart Syndrome Guidelines Task Force

Nelson Alphonso[a], Annalisa Angelini[b,†], David J. Barron[c,†], Hannah Bellsham-Revell [d,†], Nico A. Blom[e,†], Katherine Brown[f], Deborah Davis [g,h], Daniel Duncan[h], Marny Fedrigo[i,†], Lorenzo Galletti[j,†], David Hehir[k], Ulrike Herberg [l,†], Jeffrey P. Jacobs[m,†], Katarzyna Januszewska[n,†], Tom R. Karl [o,*†] (Chaiman HLHS Guidelines Task Force), Edward Malec[n,†], Bohdan Maruszewski [p,†], James Montgomerie[q], Christian Pizzaro[h,r,†], Dietmar Schranz[s,†], Amanda J. Shillingford [t] and John M. Simpson[u,†]

HLHS:epidemiology

- Survival is currently around 65% at5years ofageand55%at10years of age.
- Hypoplastic left heart syndrome is rare, accounting only for 2–3% of all congenital heart diseases and occurring in about 2 in every 10 000 livebirths (studies vary from 1·5 to 6·7 per 10 000 livebirths),
- No gene is specific to hypoplastic left heart syndrome. However, several genetic associations have been identified but without any consistent marker. Associations with sporadic cases of the syndrome include connexin protein 43 (also known as gap junction protein α1 or GJA1), a lesion at 11q23 and a cardiac homeobox transcription factor NKX2.
- Chromosomal anomalies have also been linked to the syndrome in up to 5–12% of cases, with monosomy X (Turner's syndrome) and trisomy 18 or 13 being common, but the most common is in terminal 11q deletion (Jacobsen's syndrome) in which 10% of all children born have hypoplastic left heart syndrome. Hypoplastic left heart syndrome has been described as one of at least 32 syndromes.
- Various more complex morphological features might occur together with hypoplastic left heart syndrome—such as transposition of the great vessels, atrial isomerism, and total anomalous pulmonary venous drainage—in about 7·5% of all cases.

HLHS: definition

- HLHS encompasses a heterogeneous group of congenital cardiac anomalies characterized by the presence of a hypoplastic or virtual left ventricle, usually not forming the apex of the heart, with aorta and/or mitral hypoplasia or atresia.
- The common feature of HLHS is a functional single right ventricle chamber.
- The physiological consequence is that systemic blood flow is provided (completely or partially) by the RV via an arterial duct.
- The AD and an adequate mixing at the atrial level are essential for postnatal survival.

HLHS: definition

- No genotype phenotype correlation exists so far.
- No gene is specific to hypoplastic left heart syndrome (connexin 43, a lesion at 11q23 and a cardiac homeobox transcription factor NKX2).
- Chromosomal abnormalities can be present in up to 10% of HLHS with monosomy X (Turner's syndrome) and trisomy 18 or 13 being common, but the most common is in terminal 11q deletion (Jacobsen's syndrome)

Hypoplastic Left Heart Syndrome

- Mitral atresia
- Aortic atresia
- Mitro-aortic atresia
- Hypoplastic left ventricle complex

HLH syndrome versus HLH complex

There is a spectrum of severity in the structural abnormalities

- HLH complex is the milder form of HLHS and represents underdevelopment of the left heart with significant hypoplasia of the LV and AoV or MV, or both valves, and with hypoplasia of the Asc Ao and Ao arch.

Left ventricle : spectrum of morphological abnormalities

- A ‘slit-like ventricle’

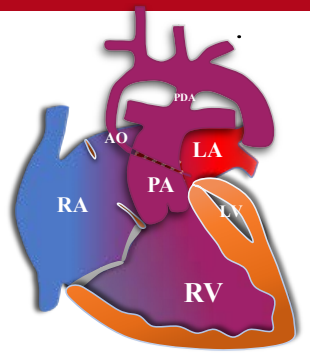

A

- A ‘miniature LV’ but not forming the cardiac apex

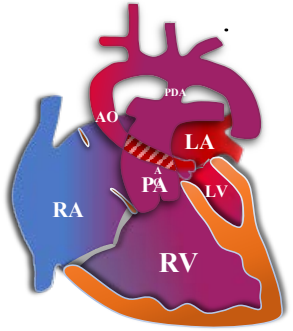

B

- A ‘small LV cavity with a thick parietal wall and Endocardial Fibroelastosis (EFE)

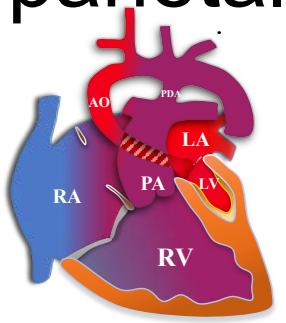

C

- LV ‘dilation’ associated with mitral regurgitation,

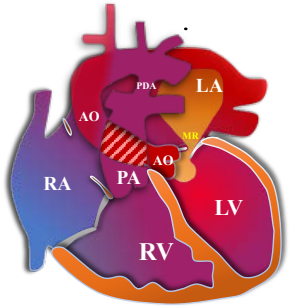

D

Left ventricular morphology: slit-like ventricle

- a flattened, virtual LV within the left posterolateral aspect of the ventricular mass, which can be identified indirectly by the coronary vessels on the epicardial surface encircling the LV as happens in the normal heart.

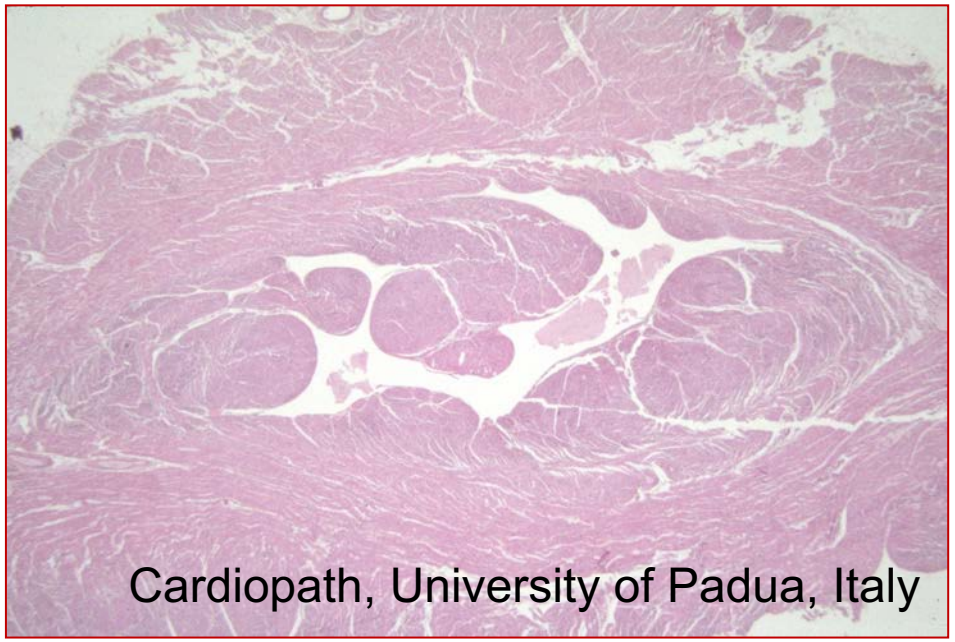

HLHS: virtual ventricle

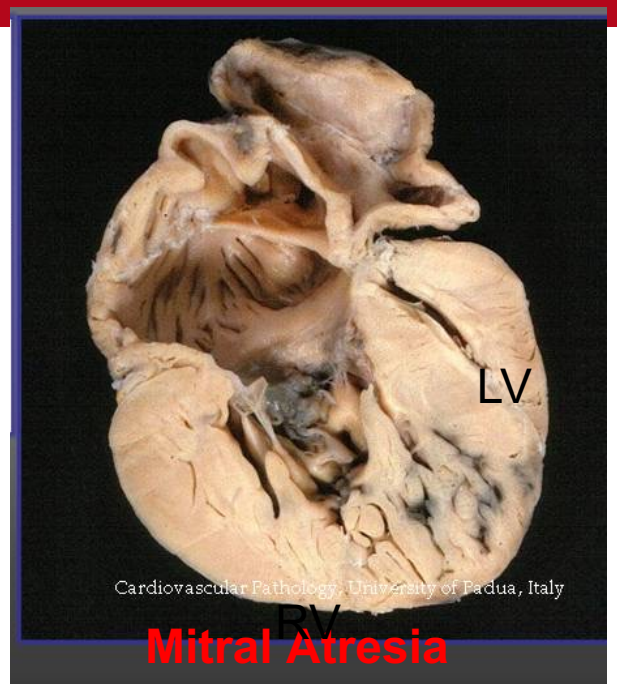

- No valve tissue at AV junction
- No endocardial fibroelastosis (EFE) in LV.
- The atrioventricular (AV) junction is muscular.

Left ventricular morphology: miniature LV

- A nearly normal size LV and parietal thickness but not forming the cardiac apex
- Anatomically normal Aortic and mitral Valve (i.e. small, minute)
- It occurs in Mitral Stenosis and Aortic Stenosis

Left ventricular morphology: small LV

- A ‘small LV cavity with a thick parietal wall’, associated with a wide range of AoV malformations, either stenotic or atretic, and Mitral Stenosis

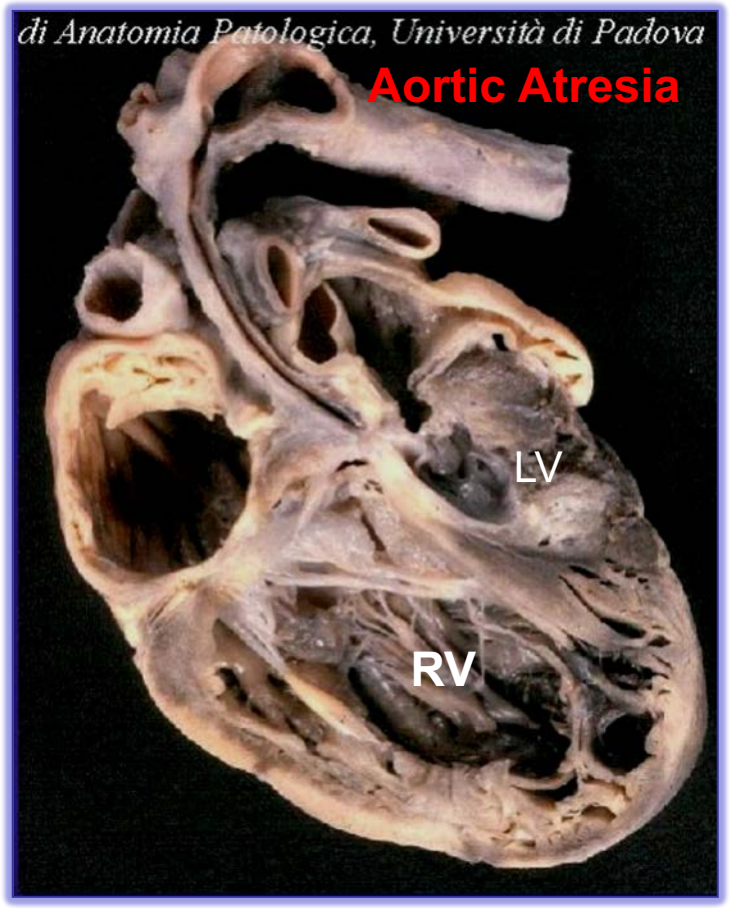

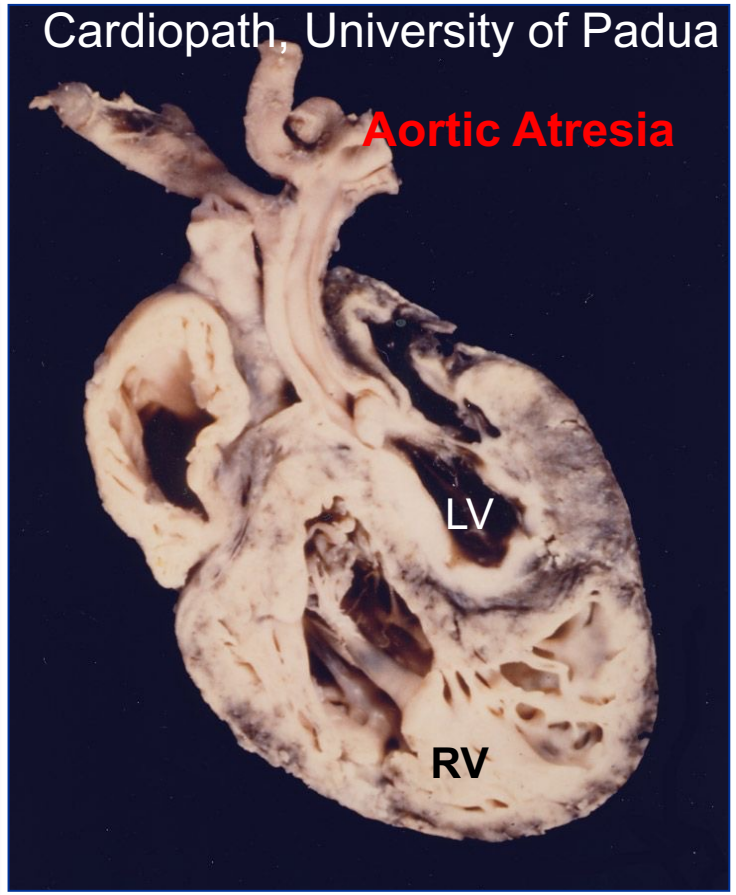

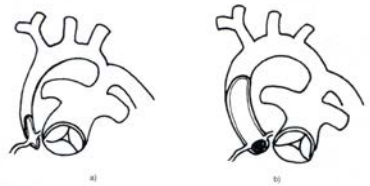

Cul de sac Dome like aortic valve

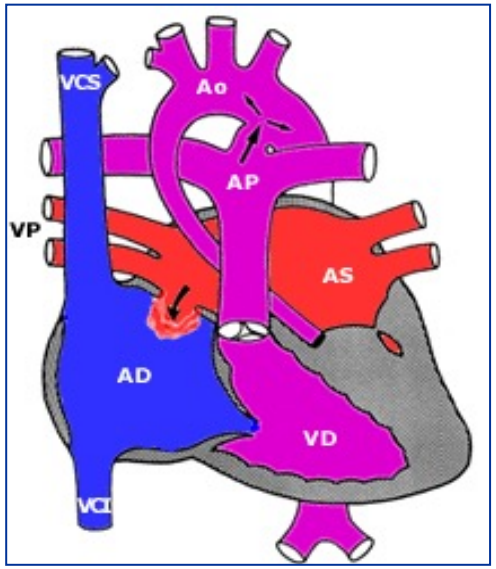

HLHS : FIBROELASTOTIC LEFT VENTRICLE

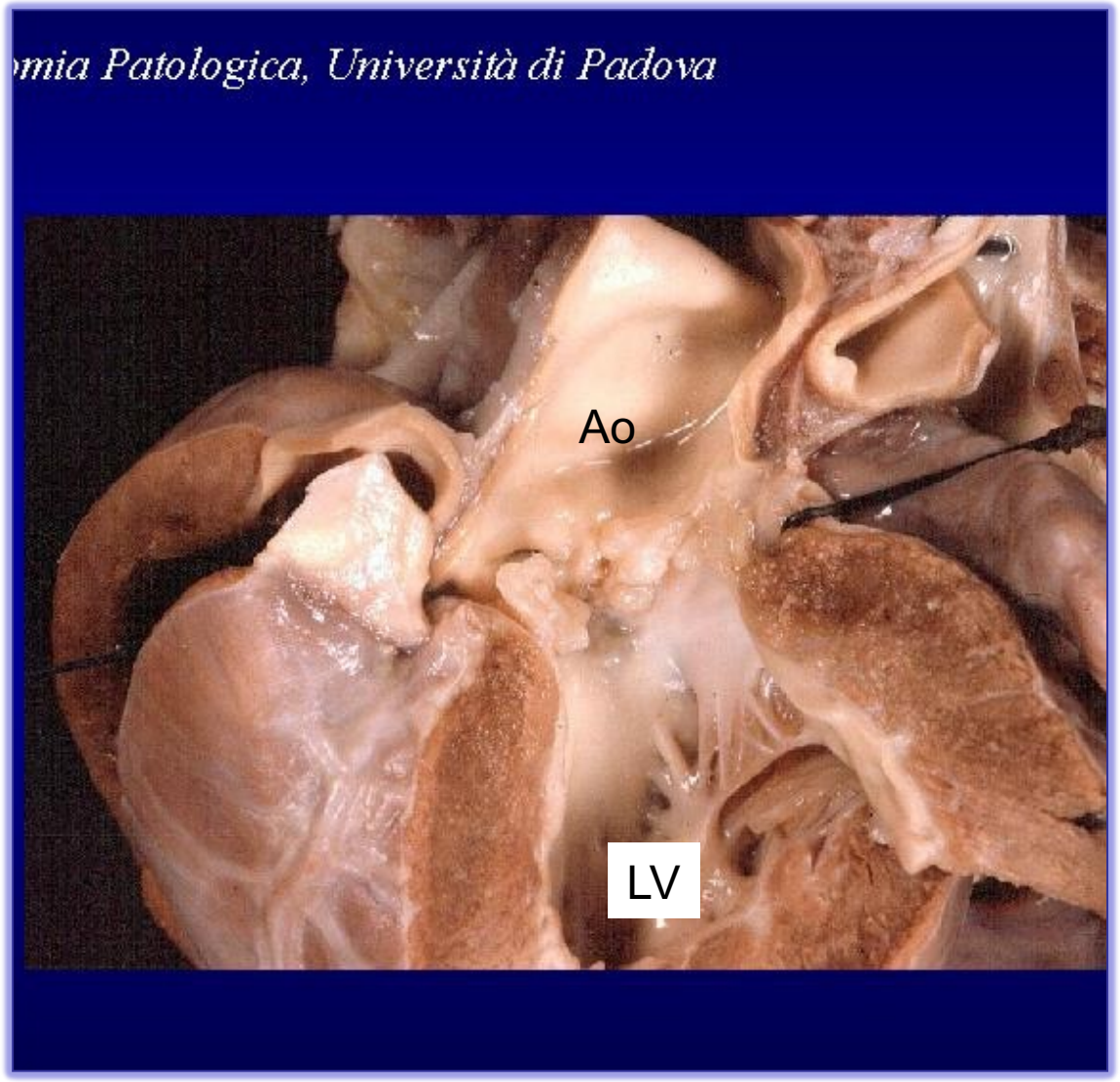

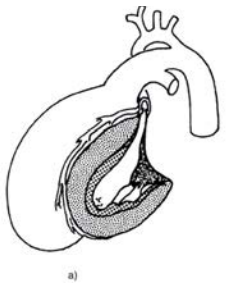

EFE is usually recognizable as a firm, whitish layer on the LV endocardial surface that, besides the thick parietal wall, further contributes to the stiffness of the LV.

Left ventricular morphology: dilated LV

- mitral regurgitation, with leaflet redundancy, thin LV parietal wall and giant left atrium (LA), which can produce right chamber compression.

Aortic valve morphology: stenosis

- Number of leaflets abnormalities
  - Unicuspid
  - Bicuspid
  - Quadricuspid
- Dysplastic

Aortic valve morphology

- An intrinsically stenotic commissural orifice
- A small aortic ring diameter
- A dysplastic leaflet with myxoid nodular excrescences

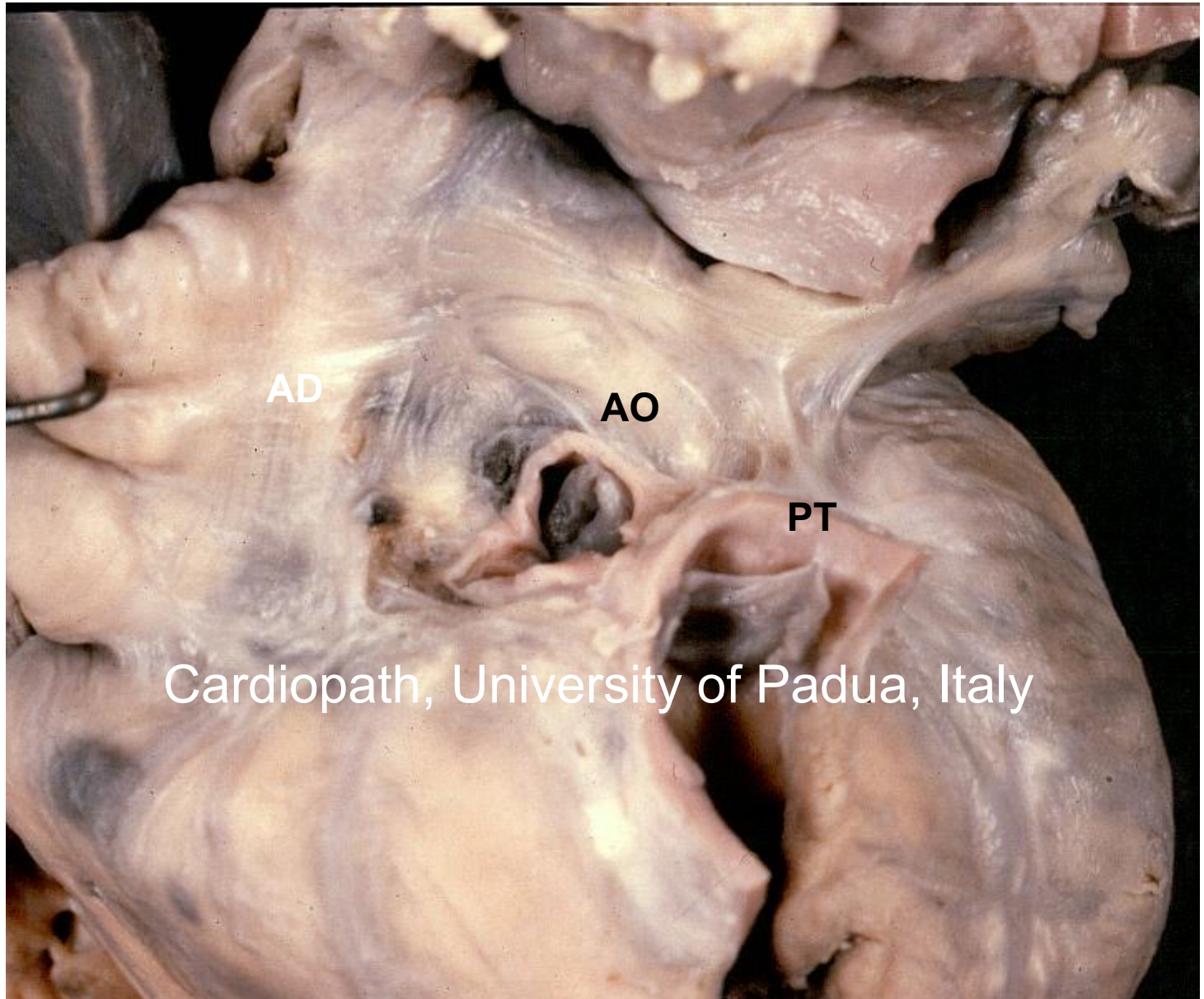

Aortic valve morphology

Narrow outflow tract , often sigmoidal

Dysplastic, stenotic aortic valve

Hypoplasia of the left ventricle.

Mitral valve and Ao dysplastic valve

Mitral valve , with short or absent tendineous cords

Anomalies of the papillary muscle Arcade, or parachude type

Leaflets dysplastic with nodular mixoid excrescences

Atrial cavity&atrial septum in HLHS with intact or r-FO

- Type A: A relatively large LA with a thick

septum secundum and a thin septum primum adherent to each other, often associated with a leftward and posteriorly deviated septum primum, and dilated pulmonary veins.

- The decompression pathway from the LA can be to the innominate vein, the right superior vena cava and the RA. This pathway is unobstructed.

Question 2

Which is the missing structure in this atrial cavity ?

A Inferior caval vein

B Superior caval vein

C Foramen Ovale

D Coronary sinus

Atrial cavity&atrial septum in HLHS with intact or r-FO

- Type B: A relatively small, muscular LA with circumferential thickening of the atrial walls and a thick ‘spongy’ muscular atrial septum without distinction between the septum primum and septum secundum.
- The LA appears muscular and the pulmonary veins are usually small.

Restrictive FO

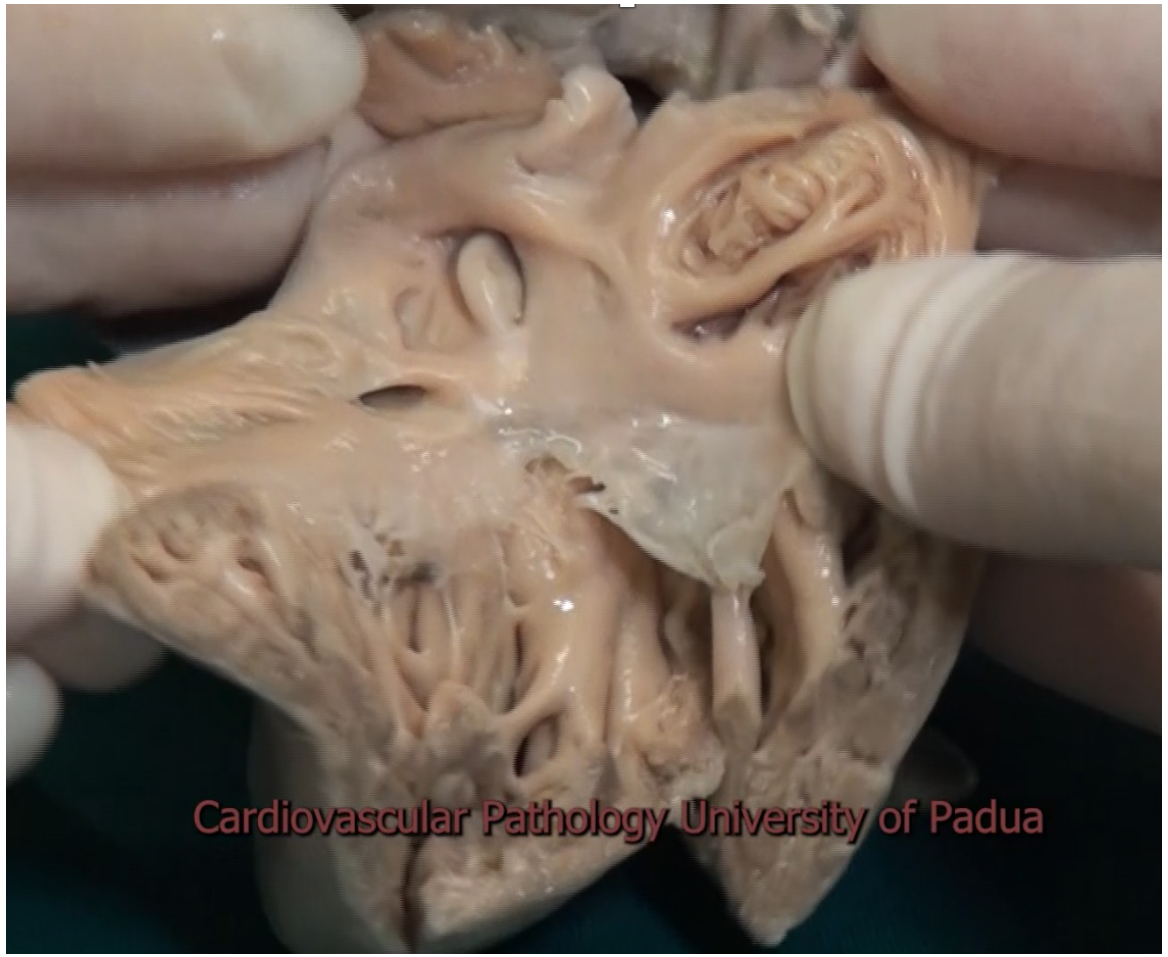

left atrial and consequently pulmonary venous hypertension results in markedly pathological remodeling of pulmonary vasculature during gestation, including pulmonary arterial hypertrophy, arterialization of pulmonary veins and intrapulmonary dilatation of lymphatic vessels

Atrial cavity&atrial septum in HLHS with intact or r-FO

- Type C: A giant LA with a thin, rightwards bulging septum & identifiable septum primum and secundum, in the setting of severe mitral regurgitation.
- The pulmonary veins are usually large.

HLHS and TR Valve morphology

Frequency of dysplasia of the tricuspid valve in relation to the subtypes of HLHS

Subtype of HLHS	TV-dysplasia		
	Moderate	Severe	None
MA/AA ($n = 38+1$)	6 (15%)	0 (0%)	33 (85%)
MS/AA ($n = 27$)	13 (48%)	0 (0%)	14 (52%)
MS/AS ($n = 16$)	8 (50%)	2 (12%)	6 (38%)
Total ($n = 82$)	27 (33%)	2 (2%)	53 (65%)

AA, aortic atresia; AS, aortic stenosis; HLHS, hypoplastic left heart syndrome; MA, mitral atresia; MS, mitral stenosis; TV, tricuspid valve.

C. Stamm et al. / European Journal of Cardio-thoracic Surgery 12 (1997) 587–592

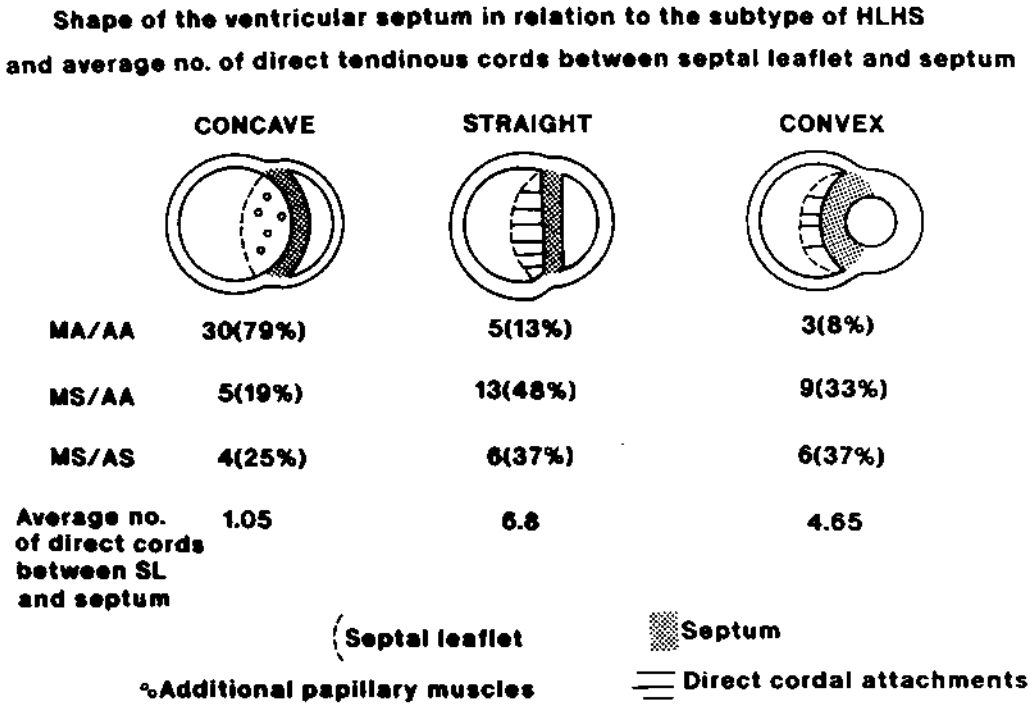

Fig. 3. Diagram depicting the three shapes of the ventricular septum as viewed from the apex of the heart in relation to the variations in attachments of the septal leaflet. MA/AA, combined mitral and aortic atresia; MS/AA, mitral stenosis with aortic atresia; MS/AS, combined mitral and aortic stenosis.

Once significant TR and/or RV dysfunction ensues, there is a two- to three-fold risk of death and/or transplant.

Dysplasia of the Tricuspid valve

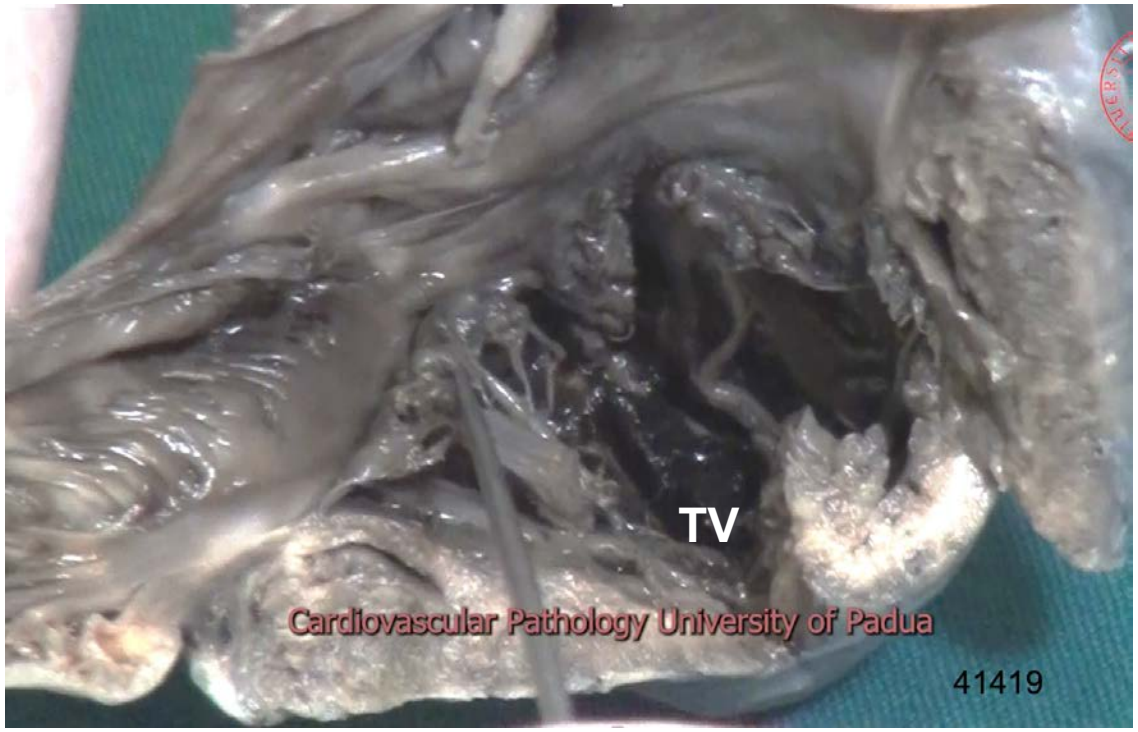

Key points

- Terminology for HLHS
- LV morphology: four types from virtual to dilated cavity
- Aortic valve morphology in the setting of atresia and stenosis: dysplasia & hypoplasia with underdeveloped orifice
- Left atrium and atrial septum morphology
- Right ventricle & abnormal tricuspid valve morphology
- The term HLHS recognises that the components that make up the left heart are all interrelated in their function and development, so that no single component can be considered in isolation

annalisa.angelini@unipd.it